
A CONSERVATION APPROACH TO PHARYNGEAL CARCINOMA WITH ADVANCED NECK DISEASE: OPTIMIZING NECK MANAGEMENT

Abdelkarim S. Allal, MD,¹ Pavel Dulguerov, MD,² Sabine Bieri, MD,¹ Willy Lehmann, MD,² John M. Kurtz, MD¹

¹ Division of Radiation Oncology, University Hospital of Geneva, 1211 Geneva 14, Switzerland

² Division of Head and Neck Surgery, University Hospital, Geneva, Switzerland

Accepted 8 June 1998

Abstract: *Background.* Surgical management of advanced neck disease remains controversial when a conservative approach based on radiotherapy is retained for primary tumors. The objective of this study was to evaluate retrospectively treatment results in pharyngeal cancers presenting with N2–N3 neck disease, using neck dissection followed by radical locoregional radiotherapy (RT) and to compare these results with those obtained in patients treated by radical RT alone.

Methods. From August 1991 to November 1996, 41 patients with carcinomas of the oro- or hypopharynx were staged as T1–T3 N2–N3 M0 (American Joint Committee on Cancer [AJCC] stage IV). Twenty-four patients were treated with neck dissection followed by RT (group 1) and 17 patients with radical RT (group 2) using a progressively accelerated concomitant boost schedule. Chemotherapy was delivered to 6 patients in group 1 and 8 in group 2 partially concomitantly with RT.

Results. Three-year actuarial locoregional control was 73% and 55% for groups 1 and 2, respectively ($p = .52$). The corresponding 3-year actuarial overall survival rates were 37% and 50% ($p = .42$). Severe postoperative complications were observed after neck dissection in four patients (16%). Acute toxicity during RT was similar in the two groups. Late toxicities were also

similar, except for two patients in group 1 who developed severe laryngeal edema.

Conclusions. Neck dissection followed by radical RT to the primary tumor and neck represents a valid treatment option in this subset of patients, allowing good control of advanced neck disease, while at the same time conserving pharyngolaryngeal function. However, for patients who are at high risk of severe postoperative complications, radical RT can be considered a worthy alternative, particularly for oropharyngeal carcinomas. © 1999 John Wiley & Sons, Inc. *Head Neck* 21: 217–222, 1999.

Keywords: radiotherapy; neck dissection; pharynx cancer

Cervical lymph node status is the most important prognostic factor in head and neck cancers. The therapeutic approach considered for the lymph nodes is usually determined by the management of the primary tumor. For N0–N1 neck disease, elective or therapeutic neck dissection or radical radiotherapy (RT) are used individually and yield similar results.^{1,2} However, for nodes larger than 3 cm, cure rates decrease progressively with increasing nodal volume,^{3,4} and control of neck disease is often unsatisfactory using a single modality. In this category of patients, the therapeutic approach remains controversial, al-

Presented at the 1st International Symposium on Metastases in Head and Neck Cancer, January 15–18, 1998, Kiel, Germany.

Correspondence to: A. S. Allal

CCC 1043-3074/99/030217–06
© 1999 John Wiley & Sons, Inc.

though surgery remains the first line of treatment in most institutions.

Some patients with extensive nodal involvement are initially seen with pharyngeal tumors of limited volume, suitable for treatment with radical RT. For patients in whom RT is considered appropriate treatment of the primary tumor, therapeutic options for advanced neck disease include combined neck dissection and RT or radical RT alone. Since the end of the 1970s, preference has been given in our institution to the combination of neck dissection followed by RT, although for various reasons, some apparently comparable patients were treated primarily with radical RT. The purpose of this article was to analyze the results of these two treatment attitudes in a subset of patients recently treated in a homogeneous fashion using a concomitant boost accelerated RT schedule.

PATIENTS AND METHODS

Patient Selection. From August 1991 to November 1996, 41 patients with carcinomas of the oropharynx or hypopharynx were staged as T1–T3 N2–N3 M0 (American Joint Committee on Cancer [AJCC] stage IV) at time of initial clinical evaluation and were subsequently treated with concomitant boost RT. Initial evaluation usually included physical examination, computerized tomography and/or magnetic resonance imaging, and panendoscopy. The tumors were classified according to the 1987 Union International Contre le Cancer (UICC) TNM classification.⁵ The choice of treatment approach was made by a multidisciplinary tumor board. Although neck dissection followed by RT was the preferred approach, some patients were treated primarily with radical RT despite the presence of advanced neck disease. Although the reasons for this decision were not always precisely documented, they included refusal of surgery, patient unsuitability for surgery, and situations judged relatively favorable for radiotherapy. Thus, 24 patients were treated with neck dissection followed by RT (group 1) and 17 patients with radical RT (group 2). Chemotherapy was administered to a small number of patients in both groups. The histology, determined by biopsy, was squamous cell carcinoma in all patients but one (undifferentiated carcinoma) in group 2. A comparison of patient characteristics is presented in Table 1 for the two groups.

Surgery. Twenty-three patients had a radical neck dissection, which was unilateral in 21, bilat-

Table 1. Patient characteristics in the two groups.

Parameter	Group 1 (n = 24)	Group 2 (n = 17)	p
Mean age (SD), y	57 (± 7.5)	59 (± 9.5)	.39
Male/female	23/1	9/8	
WHO Performance status			
0–1	19	13	
2–3	5	4	
Tumor location			
Oropharynx	11	14	.02
Hypopharynx	13	3	
Clinical T stage			
T1	13	2	
T2	6	4	
T3	5	11	.008
Clinical N stage (pathologic)			
N1 (pN1)	0 (2)	0	
N2a (pN2a)	9 (4)	5	
N2b (pN2b)	7 (16)	4	
N2c (pN2c)	0 (1)	5	
N3 (pN3)	8 (1)	3	
Clinical maximal node size (cm)			
Mean (SD)	4 (± 1.8)	4 (± 2.3)	.93
Extracapsular tumor spread			
Yes	16		
No	3		
Unstated	5		

SD = standard deviation.

eral in 1, and associated with a contralateral modified radical dissection in 1 patient. One patient had a modified radical neck dissection. Because of tumor involvement, the radical neck dissection was extended to encompass the common carotid artery in 1 patient, the external carotid artery in 1 patient, the parotid gland in 1 patient, the cervical sympathetic chain in 1 patient, the hypoglossal nerve in 2 patients, and cervical skin in 3 patients. Otherwise, surgery was reserved for salvage of locoregional failures in the two groups. The median interval between neck dissection and RT was 28 days (range, 19–75 days). In patients with postoperative complications (see RESULTS), this median interval was 35 days (range, 22–75 days).

Radiotherapy. The treatment schedule has previously been described in detail.⁶ Briefly, a total dose of 69.9 Gy in 41 fractions over a period of 38 days was planned by using a modified concomitant boost schedule. The basic course delivered 50.4 Gy over 5.5 weeks (1.8 Gy/day, five times a week) to the primary tumor area and both sides of the neck down to the clavicles. A boost of 19.5 Gy (13 × 1.5 Gy) to the initially involved sites was given as a second daily fraction, starting the last

day of the second week of the basic treatment, in a progressively accelerated fashion. The minimum interval between the two daily fractions was 6 hours.

All patients were treated with 6 MV photon beams, using two opposed laterals and one anterior field for the larger volume, whereas the treatment technique for the boost was individualized according to the tumor extent and location. A tissue equivalent bolus was used in group 1 patients to insure an adequate dose to the cervical scar, and a localized electron field boost was given to the part of the scar that was outside the photon boost fields. No specific technical modifications were used in the group of patients receiving chemotherapy.

Chemotherapy. In the absence of medical contraindications, chemotherapy was usually offered to patients with T3 or N3 tumors. Thus, chemotherapy was delivered to 14 patients: 6 in group 1 and 8 in group 2. In one case (in group 1), chemotherapy was administered prior to, and in 13 concomitantly with RT, either alone or with neoadjuvant and/or adjuvant chemotherapy. Twelve patients received cisplatin 100 mg/m², either alone (1 patient) or associated with 5-fluorouracil, 1000 mg/m² daily for 5 days (11 patients), and two patients received weekly carboplatin (150 mg/week). The median number of cycles was three (range, 2–5).

Statistical Methods. Actuarial overall and disease-free survival rates as well as actuarial local, regional, and locoregional control rates were calculated by using the Kaplan-Meier method.⁷ Fisher's Exact test, the unpaired *t* test, and the log rank test were used to assess for significant differences between simple proportions, means, and survival curves, respectively.

RESULTS

In patients receiving simultaneous chemotherapy and RT, acute toxicity resulted in temporary interruption of treatment in two patients and premature termination of RT in one patient, all in group 2. Otherwise, RT was conducted essentially as planned. The median overall treatment time was 41 days for both groups (range, 37–62 days). The median tumor dose for both groups was similar (69.9 Gy; range, 62.5–70.6 Gy). The median dose to involved nodes was also similar for both

groups (69.9 Gy), with ranges of 56.4 to 70.4 Gy in group 1 and 67.5 to 69.9 Gy in group 2.

Morbidity. In group 1, moderate to severe postoperative complications were observed in 9 patients (37%). One patient was seen with an iatrogenic facial paralysis, 1 with a sensory-motor syndrome due to a cerebral vascular accident, 1 with repeated syncope as a consequence of surgical trauma to the vagus nerve, and 3 with delayed wound healing due to skin necrosis. All these 6 patients had an extended radical neck dissection for resection of involved structures. Other postoperative complications included 1 patient with atrial fibrillation requiring anticoagulation and cardioversion, 1 patient with persistent left phrenic paralysis, and 1 patient with temporary paralysis of the marginal branch of the facial nerve.

All acute reactions due to radiotherapy ± chemotherapy were grade 2 or more according to the grading system of the Radiation Therapy Oncology Group (RTOG).⁸ The majority were grade 3 reactions (80% of cases), with one patient in group 2 having grade 4 acute toxicity. No significant difference was observed between the two groups.

Two patients died during the 3 months following radiotherapy of causes not clearly related to tumor progression. One patient, who refused supportive care, died of malnutrition (group 1), and one patient died from a massive oropharyngeal hemorrhage in a setting of postchemotherapy thrombopenia (group 2). Most late complications were RTOG grade 2, with no significant difference between the two groups. A grade 3 complication was observed in one patient (group 1) and grade 4 in two patients (1 in each group). The two serious late complications observed in group 1 patients were laryngeal edemas.

Clinical Outcome. At last follow-up, 9 patients in group 1 and 9 in group 2 were still alive. In patients having died, head and neck cancer, complications, second cancer, and intercurrent disease were considered the causes of death in 9, 1, 4, and 1 patients, respectively, in group 1 and in 4, 1, 1, and 2 patients, respectively, in group 2. Median follow-up for surviving patients was 31 months (range, 13–49 months) and 41 months (range, 10–65 months) for groups 1 and 2, respectively. The 3-year actuarial overall survival was 37% and 50% (*p* = .42), and the 3-year disease-free survival was 60% and 51% (*p* = .81) for groups 1 and 2, respectively.

Local and locoregional control rates were estimated without taking into account the contribution of salvage surgery. Three-year actuarial local control was 81% in group 1 and 75% in group 2 ($p = .97$), and actuarial locoregional control was 73% and 55% for groups 1 and 2, respectively ($p = .52$) (Figure 1). Two regional recurrences in group 1 and 1 local recurrence in group 2 were treated palliatively, and radical salvage surgery was performed for regional recurrence in 2 patients in group 2, leading to persistent control in 1. The 3-year regional control rate after salvage was 78% and 69% in groups 1 and 2, respectively ($p = .8$).

DISCUSSION

Pharyngeal carcinomas of small to moderate volume are suitable for conservative treatment by RT. Reflecting the biologic heterogeneity of these cancers, however, some patients with limited primary tumors are initially seen with advanced nodal metastases. In this setting, the therapeutic approach is problematical, because radiocurability decreases with increasing node size.^{9,10} Several treatment modalities can be considered, such as initial surgery for both the primary tumor and lymph nodes followed by postoperative RT,¹¹ radical RT with or without a planned neck dissection,^{10,12} or therapeutic neck dissection followed by radical RT for the primary tumor.^{13,14} This latter approach represents a true spatial cooperation between surgery and RT, offering the established advantages of combined treatment to the advanced neck disease, while at the same time conserving pharyngolaryngeal function. Although few series have been published to report the results of such an approach, it is likely that this

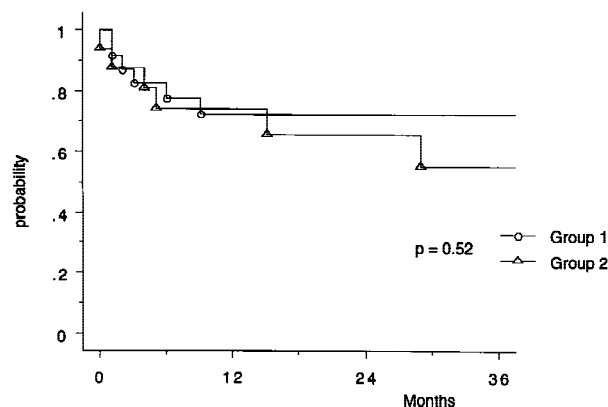


FIGURE 1. Actuarial locoregional control in the two groups (group 1 = neck dissection + radiotherapy; group 2 = radical radiotherapy alone).

treatment option is used more frequently than reported. For example, in Geneva, this approach has been used in nearly 50 patients with T1–T3 N2–N3 pharyngolaryngeal cancers since the end of the 1970s. The current study is limited to pharyngeal cancers treated during the past 5 years with a rigorously defined accelerated RT schedule, comparing the outcome after combined therapy with that observed after radical RT alone.

The 3-year actuarial local control rate was comparable in both groups (81% versus 75%) and was similar to those reported in the literature.^{11,13} The 3-year locoregional control rate appeared to be higher in group 1, although the difference was not significant (73% versus 55%). Moreover, regional control after salvage surgery was similar in the two groups, and the apparent gain in initial locoregional control did not translate into a significant improvement in overall survival. Nonetheless, the results of this small retrospective study should be interpreted with caution, particularly considering the differences in tumor sites and T-stage distribution between the two groups. Indeed, although patients in group 2 had more T3 tumors, more hypopharyngeal carcinomas were found in group 1, perhaps negatively influencing overall survival. Also, group 2 included more neck metastases from oropharyngeal tumors, which have been suggested to be more radiocurable.³ Finally, the median of the maximum node diameters was larger in group 1 (4 cm versus 3 cm), despite equivalent mean values. It is thus possible that the patients selected for therapeutic neck dissections had generally less favorable prognoses than did those of patients in group 2.

A comparison of our results with those of other series is of limited value because of considerations of patient selection. The French Head and Neck Study Group¹¹ conducted a retrospective study comparing results of different modalities used in the treatment of T1–T2 pharyngolarynx carcinomas with palpable nodes. A significantly higher 3-year regional recurrence-free survival was observed in 65 patients treated with neck dissection followed by RT than in 195 patients treated with radical RT alone (86% versus 62%, $p = .02$), whereas median survival was similar (19 months versus 16 months). However, in this study, N-stage and maximal node size distribution in each group, as well as patient selection criteria and the type of RT technique, were not specified. In 35

patients initially seen with lymph nodes larger than 3 cm, Byers et al¹³ reported regional and local failure rates of 11% and 28% after initial neck dissection followed by radical RT; the 5-year cancer-specific survival rate was 55%. In another small series using a similar approach, Verschuur et al¹⁴ reported no regional failure and 20% primary recurrences in 15 patients who were initially seen with involved neck nodes (mean maximal diameter, 4.5 cm). Thus, in the setting of bulky neck disease, our data and those from other similar retrospective studies suggest a tendency of combined treatment to provide superior regional control compared with that obtained with RT alone but without apparent gain in overall survival.

The delay in the treatment of the primary tumor might represent a potential disadvantage of this approach. The extent of potential primary tumor progression could not be ascertained in this retrospective study. Repeated preradiotherapy imaging might be used in the future to study this question. The negative impact of delayed treatment has been highlighted by Byers et al,¹³ who observed inferior local control when RT was delivered more than 2 weeks after neck dissection. This disadvantage has not been stressed by others,^{11,14} and in our series, local control was similar (80% versus 81%) in patients treated before and after the median interval of 28 days observed between neck dissection and RT.

Although the prognosis of this group of patients is primarily determined by the extent of nodal disease, it is advisable to begin radiotherapy as soon as possible after surgery. However, in our experience, RT was delayed in some patients as a result of serious postoperative complications, which occurred in 9 patients in group 1. In 6 of these patients, complications were the consequence of the resection of important structures involved by the cervical metastases. Another disadvantage of neck dissection when used before RT is the possibility that hypoxia induced in the dissected neck tissue might impair the radiosensitivity of the residual tumor cells. Although hypoxia in bulky and necrotic lymph nodes is now well established and known to be an adverse factor for regional control after radiotherapy,¹⁵ the relevance of these considerations in the postoperative setting is uncertain. Although the overall acute and late complications were similar in both groups, two cases of severe late laryngeal edema were noted in group 1. This

specific complication may represent another disadvantage of combined treatment. Strict patient selection for this approach is thus strongly advised, with particular emphasis placed on assessment of the involved neck structures and the patient's general condition.

CONCLUSIONS

These results suggest that neck dissection followed by radical locoregional RT represents a valid conservation approach to the treatment of small to moderate volume pharyngeal cancers (nasopharynx excluded) presenting with advanced neck disease. In light of our experience, we continue to prefer this combined approach. However, for patients judged to be at high risk of severe postoperative complications, radical RT can be considered a worthy alternative, particularly for oropharyngeal carcinomas.

REFERENCES

1. Chow JM, Levin BC, Krivit JS, et al. Radiotherapy or surgery for subclinical cervical node metastases. *Arch Otolaryngol Head Neck Surg* 1989;115:981-984.
2. Weissler MC, Weigel MT, Rosenman JG, et al. Treatment of the clinically negative neck in advanced cancer of the head and neck. *Arch Otolaryngol Head Neck Surg* 1989; 115:691-694.
3. Bernier J, Bataini JP. Regional outcome in oropharyngeal and pharyngolaryngeal cancer treated with high dose per fraction radiotherapy. Analysis of neck disease response in 1646 cases. *Radiother Oncol* 1986;6:87-103.
4. Barkley HT, Fletcher GH, Jesse RH, Lindenberg RD. Management of cervical lymph node metastases in squamous cell carcinomas of the tonsillar fossa, base of tongue, supraglottic larynx and hypopharynx. *Am J Surg* 1972; 124:462-467.
5. UICC Classification of malignant tumors. New York: Springer Verlag; 1987.
6. Allal AS, Bieri S, Miralbell R, Marchal F, Lehmann W, Kurtz JM. Feasibility and outcome of a progressively accelerated concomitant boost radiotherapy schedule for head and neck carcinomas. *Int J Radiat Oncol Biol Phys* 1997;38:685-689.
7. Kaplan EL, Meier P. Nonparametric estimation from incomplete observations. *J Am Stat Assoc* 1958;53:457-481.
8. Perez CA, Brady LW. Overview. In: Perez CA, Brady LW, editors. Principles and practice of radiation oncology. Philadelphia: Lippincott Co.; 1992. p 51-55.
9. Wolf GT, Fisher SG. Effectiveness of salvage neck dissection for advanced regional metastases when induction chemotherapy and radiation are used for organ preservation. *Laryngoscope* 1992;102:934-939.
10. Bataini JP, Bernier J, Jaulerry C, Brunin F, Pontvert D, Lave C. Impact of neck node radioresponsiveness on the regional control probability in patients with oropharynx and pharyngolarynx cancers managed by definitive radiotherapy. *Int J Radiat Oncol Biol Phys* 1987;13:817-824.
11. GETTEC. Early pharyngolaryngeal carcinomas with palpable nodes. French Head and Neck Study Group (GETTEC). *Am J Surg* 1991;162:377-380.
12. Peters LJ, Weber RS, Morrison WH, Byers RM, Garden AS, Goepfert H. Neck surgery in patients with primary

- oropharyngeal cancer treated by radiotherapy. *Head Neck* 1996;18:552-559.
13. Byers RM, Clayman GL, Guillaumondequi OM, Peters LJ, Goepfert H. Resection of advanced cervical metastasis prior to definitive radiotherapy for primary squamous carcinomas of the upper aerodigestive tract. *Head Neck* 1992;14:133-138.
 14. Verschuur HP, Keus RB, Hilgers FJM, Balm AJM, Gregor RT. Preservation of function by radiotherapy of small primary carcinomas preceded by neck dissection for extensive nodal metastases of the head and neck. *Head Neck* 1996;18:277-282.
 15. Gatenby RA, Kessler HB, Rosenblum JS, et al. Oxygen distribution in squamous cell carcinoma metastases and its relationship to outcome of radiation therapy. *Int J Radiat Oncol Biol Phys* 1988;14:831-838.