

---

How I Do It

## Head and Neck and Plastic Surgery A Targeted Problem and its Solution

---

# Interventional Sialendoscopy

---

Francis Marchal, MD; Minerva Becker, MD; Pavel Dulguerov, MD; Willy Lehmann, MD

### INTRODUCTION

The classic attitude toward sialolithiasis is an anti-biotic and anti-inflammatory treatment, hoping for a spontaneous stone expression through the papilla. In cases of submandibular stones located close to the opening of Wharton's duct, a marsupialization of the papilla is performed and the stone removed. In cases of parotid stones, a conservative approach is adopted whenever possible, because parotidectomies for infectious conditions are associated with a higher incidence of facial nerve complications.<sup>1,2</sup> Nevertheless, in case of recurrent infections, and of posteriorly located stones, parotidectomy was the only option. Because of the morbidity of both operations, the surgeon and, more often, the patients are reluctant to proceed to surgery. However, a longer delay before definitive treatment leads to stone enlargement and fibrosis of the gland and therefore greater surgical risk.

The first reports of a distal submandibular stone extraction were published by radiologists in the early 1990s: the procedure was performed with a wire basket.<sup>3,4</sup> The first parotid stone extraction was performed in 1994 by Sharma et al.<sup>5</sup> In both cases the stone was extracted blindly.

We report on a new, minimally invasive technique of salivary duct exploration and treatment under direct endoscopic control. Sialendoscopy aims to visualize the lumen of the salivary ducts and their diseases. Interventional sialendoscopy aims to treat salivary ductal diseases, mainly removing salivary stones.

### TECHNIQUE

Sialendoscopy<sup>6</sup> is performed with the patient under local anesthesia and uses semirigid custom-made instruments. The general principle is that endoscopy is performed

with continuous rinsing by means of a local anesthetic solution flowing around the optic fiber. This dilates the ductal lumen and provides for local anesthesia and cleaning of the endoscope tip. Diagnostic sialendoscopy is performed with a single channel device, while interventional sialendoscopy is performed with a double channel device, allowing the use of instruments under endoscopic control.

The procedure begins with topical anesthesia (Xylocaine 10%) around the papilla. A salivary sound is introduced in the duct. A peripapillary infiltration is performed with a regular local anesthetic solution. Whenever possible, a progressive dilation of the duct is performed with a dilator, although sometimes a small papillotomy of the first 5 mm is performed, mostly for Wharton's ducts.

The diagnostic sialendoscope is inserted in the dilated papilla. The rinsing solution described earlier consists of a mixture of 20 mL of lidocaine 2% and 20 mL of NaCl 0.9%. The small diameter of the device allows a complete exploration of the ductal system, often beyond the obstruction or stenosis.

When a stone is located (Fig. 1), we use the interventional sialendoscope with two channels: one for the same optic fiber used during the diagnostic procedure and the other for the grasping basket (Fig. 2) or a laser fiber, or for a dilation balloon. When the stone has a diameter smaller than 4 mm, the grasping basket is opened behind the stone. Once the stone is trapped (Fig. 3), the whole device is removed. When the stone is larger than 5 mm, fragmentation before extraction is required and can be performed either by external lithotripsy<sup>7</sup> or by laser fragmentation.<sup>8</sup> After the last stone is removed, the endoscope is introduced one final time to rinse the duct and verify its integrity.

The intervention is performed with the patient under oral antibiotic prophylaxis. Antibiotics (amoxicillin-clavulanic acid or clindamycin) and corticosteroids (prednisone 50 mg/d per os) are given for 48 hours. Frequent self-massages of the gland are recommended for the first few days. A follow-up visit is scheduled 10 days after the procedure.

---

From the Divisions of Head and Neck Surgery (F.M., P.D., W.L.) and Division of Diagnostic Radiology (M.B.), Geneva University Hospital, Geneva, Switzerland.

Editor's Note: This Manuscript was accepted for publication October 15, 1999.

Send correspondence to Pavel Dulguerov, Division of Head and Neck Surgery, Geneva University Hospital, 24, rue Micheli-du-Crest, 1211 Geneva 14, Switzerland.

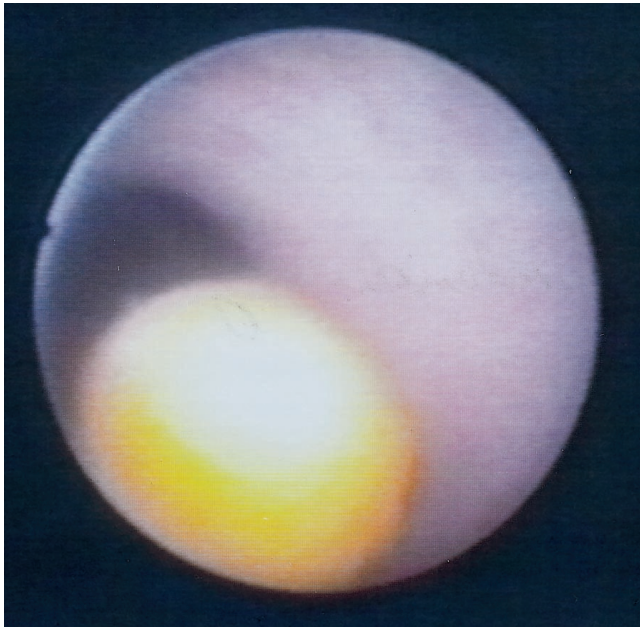


Fig. 1. Sialendoscopy of Stensen's duct showing a peripheral stone.

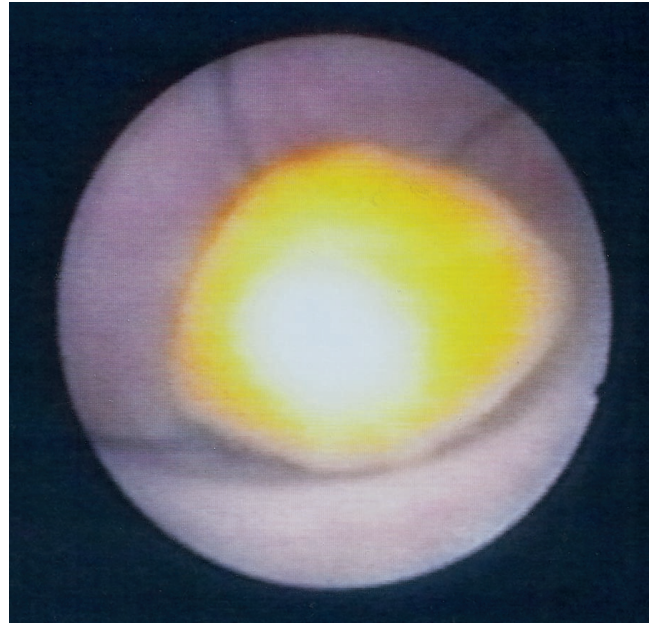


Fig. 3. Sialendoscopy showing the retrieval of the stones.

## DISCUSSION

We have been perfecting the procedure since 1996. Our overall success rate in treating sialolithiasis is 75% and depends mainly on the size of the stone. However, in about 30% of patients, more than one procedure is required.

In more than 100 interventional endoscopies<sup>6</sup> we have not encountered any significant complication, such as damage to the facial or lingual nerves, gross hemorrhage, or major duct wall perforations. Nevertheless, in two parotid sialendoscopic procedures we encountered an impaction of the grasping basket, which could be removed by firm traction. The persistence of such an impaction could require an open gland excision, a risk to be explained to patients. In three cases, the stone was partially embedded in the duct wall and during its removal a ductal




Fig. 2. Tip of the interventional semirigid sialendoscope, with the grasping basket in place.

perforation occurred and resulted in temporary painful localized swelling. All cases resolved with conservative treatment.

In the postoperative period, we had no serious infections requiring intravenous treatment or postoperative strictures leading to a surgical removal of the gland. One patient (a bassoon player) required a large sialodochoplasty of Stensen's papilla because of ductal fibrosis and stricture of the papilla. Postoperatively, repeated parotid swellings (pneumoparotiditis) occurred during whistling, and recurrent intraglandular burning was present during meals. We had to perform a parotidectomy with ligation of Stensen's duct. Therefore special attention should be taken in minimizing papillotomy and sialodochoplasty for patients who tend to routinely increase their intraoral pressures, such as wind instrument players.

The main technical limitation of interventional sialendoscopy at the present time is the diameter of the endoscope: salivary stones too posteriorly located or a fibrosed canal wall with a reduced diameter renders the progression of the endoscope difficult. Some authors, also using rigid instruments, have reported cases of both submandibular and parotid endoscopy with 2 to 2.7-mm-diameter endoscopes.<sup>9</sup> In our experience, even with dilations and rinsing, we could not introduce endoscopes larger than 2.0 mm and these endoscopes could not reach the intraglandular part of the canal. Furthermore, Zenk et al.<sup>10</sup> reported diameters of Stensen's duct between 0.5 and 1.5 mm in 25 human cadavers.

Manipulation of the rigid sialendoscope is delicate, requires extensive experience, and might be hazardous, because of the theoretical risks of perforation or vascular or neural damages. Advancement of the endoscope in the duct should be performed only under adequate vision.

Sialendoscopy is a useful diagnostic procedure for any parotid or submandibular swelling of unclear origin.

Because these procedures are new, the exact indications remain to be more precisely defined. It might become the investigation of choice for diseases affecting the salivary ducts, replacing the current investigations such as sialography. The main indication of interventional sialendoscopy is actually the extraction under optical control of salivary stones. Its role in other ductal diseases, such as stenosis, has been described<sup>11</sup> but remains to be defined.

## CONCLUSION

Diagnostic sialendoscopy is a new, minimally invasive technique, which may become the investigational procedure of choice for salivary duct diseases. Further miniaturization of the instrumentation will allow deeper ductal exploration.

Interventional sialendoscopy under local anesthesia is a new outpatient procedure, allowing the extraction of the majority of sialoliths and therefore preventing salivary gland excisions. Further miniaturization of the instrumentation will allow fragmentation of bigger stones and extraction of more deeply located stones.

## BIBLIOGRAPHY

1. Dulguerov P, Marchal F, Lehmann W. Postparotidectomy facial nerve paralysis: possible etiologic factors and results

- with routine facial nerve monitoring. *Laryngoscope* 1999; 109:754-762.
2. Bron LP, O'Brien CJ. Facial nerve function after parotidectomy. *Arch Otolaryngol Head Neck Surg* 1997;123: 1091-1096.
3. Kelly I, Dick R. Interventional sialography: Dormia basket removal of Wharton's duct calculus [technical report]. *Clin Radiol* 1990;43:205.
4. Katz P. Nouvelle thérapeutique des lithiases salivaires. *Infect Dent* 1991;73:3975-3979.
5. Sharma RK, Al Khalifa S, Paulose KO, Ahmed N. Parotid duct stone removal by a Dormia basket. *J Laryngol Otol* 1994;108:699-701.
6. Marchal F, Dulguerov P, Lehmann W. Sialendoscopy. *N Engl J Med* 2000;341:1242-1243.
7. Iro H, Schneider HT, Fodra C, et al. Shockwave lithotripsy of salivary duct stones. *Lancet* 1992;339:1333-1336.
8. Gundlach P, Scherer H, Hopf J, et al. Die endoskopisch kontrollierte Laserlithotripsie von Speichelsteinen: in-vitro-Untersuchungen und erster klinischer Einsatz. *HNO* 1990; 38:247-250.
9. Nahlieli O, Baruchin AM. Sialoendoscopy: three years' experience as a diagnostic and treatment modality. *J Oral Maxillofac Surg* 1997;55:912-918.
10. Zenk J, Hosenmann WG, Iro H. Diameters of the main excretory ducts of adult human submandibular and parotid gland: a histologic study. *Oral Surg Oral Med Oral Pathol Oral Radiol Endod* 1998;85:576-580.
11. Brown AL, Shephard D, Buckenham TM. Per oral balloon sialoplasty: results in the treatment of salivary duct stenosis. *Cardiovasc Intervent Radiol* 1997;20:337-342.