

HISTOPATHOLOGY OF SUBMANDIBULAR GLANDS REMOVED FOR SIALOLITHIASIS

FRANCIS MARCHAL, MD
MINERVA BECKER, MD

ANNE-MARIE KURT, MD
MICHAELA OEDMAN, BS

PAVEL DULGUEROV, MD
WILLY LEHMANN, MD

GENEVA, SWITZERLAND

We reviewed the clinical history of 48 consecutive patients who underwent submandibular gland removal for radiologically proven sialolithiasis. The specimens were examined by a pathologist blinded to the clinical data. A histopathologic classification into 1 of 3 grades was established by evaluating the degrees of atrophy, fibrosis, and inflammation. A correlation between the clinical and pathological variables was sought in order to define clinical variables that would predict abnormal submandibular glands that required extirpation. A significant percentage of the submandibular glands exhibited normal histologic findings. The patients with normal submandibular glands had a clinical evolution similar to that of other patients with severely damaged glands. The only clinical variable that correlated with increased histopathologic alteration was the patient's age. In view of the newly available diagnostic and therapeutic techniques for sialolithiasis, a conservative attitude to submandibular gland resection appears justified.

KEY WORDS — classification, correlation, pathology, salivary gland, sialolithiasis, surgery.

INTRODUCTION

Sialolithiasis results in a mechanical obstruction of the salivary duct, causing recurrent glandular swelling during meals, which can remain transitory or be complicated by bacterial infections.^{1,2} The classic response to sialolithiasis is antibiotic and anti-inflammatory treatment in hope of a spontaneous stone expression through the papilla.³ When the submandibular stone is located close to the Wharton's duct opening, a marsupialization of the papilla (sialodochoplasty) can be performed and the stone extracted.⁴ For posteriorly located stones, the gland is extirpated in most cases.^{2,4}

The main indications for submandibular gland removal are sialolithiasis and sialadenitis,⁵⁻⁷ which represent 69%⁵ to 89%⁷ of all indications. Although submandibular gland excision is a frequent operation, several reports demonstrate a rather high rate of complications.⁶⁻¹¹ According to Hald and Koks-Andreasen,⁶ short-term complications are experienced by 37% of patients and include, among others, temporary marginal mandibular branch paresis (18%), infection (14%), and lingual nerve deficit (5%). In the same series, long-term complications are described in 35% of patients and include scar problems (17%), reduced salivation (14%), and alterations in sensation (13%). Paresis of the marginal mandibular branch is not rare, and an incidence of definitive paralysis of 7% is cited in one report.¹²

Since submandibular gland resection is not innocu-

ous, and since a large percentage of these operations are performed for sialolithiasis, it is surprising that the indications for submandibular gland resection for sialolithiasis remain vague. While only a few studies have examined the function of salivary glands with sialolithiasis, it is believed that the glands are no longer functional.¹³ Moreover, repeated infections, posteriorly located stones, and recurrent inflammatory swelling are thought to be directly proportional to glandular dysfunction.¹⁴

Even if there is no proven link between histopathology and function, it seems reasonable to assume that salivary glands exhibiting marked histopathologic alterations are not functional, and that morphologically normal glands could be functional. Few studies have examined the histopathology of removed submandibular glands. Histopathologic criteria have been proposed, such as inflammation, atrophy, or fibrosis.^{13,15} The exact role of inflammation in salivary function is unknown. Regarding fibrosis and atrophy and their correlation to the function of the gland, it seems reasonable to assume that if glandular acini are replaced by fibrosis, or if diffuse atrophy is present, the glandular function is impaired.

The purpose of this study was to examine and classify the histopathologic changes found in submandibular glands removed for sialolithiasis, and to correlate these histologic changes to the patient's clinical history.

From the Division of Head and Neck Surgery (Marchal, Dulguerov, Oedman, Lehmann) and the Departments of Pathology (Kurt) and Radiology (Becker), Geneva University Hospital, Geneva, Switzerland.

Presented at the meeting of the American Academy of Otolaryngology-Head and Neck Surgery, New Orleans, Louisiana, September 26-29, 1999.

CORRESPONDENCE — Francis Marchal, MD, 16, Cours de Rive, 1204 Geneva, Switzerland.

TABLE 1. DISTRIBUTION OF PATIENTS BY GRADING OF SUBMANDIBULAR GLANDS ACCORDING TO DEGREE OF ATROPHY, FIBROSIS, AND INFLAMMATION

Atrophy	Inflammation	Fibrosis		
		0	I	II
0	0	4	0	0
	I	6	3	0
	II	0	0	0
I	0	0	0	0
	I	0	11	1
	II	0	4	4
II	0	0	0	0
	I	0	2	5
	II	0	0	8

See text for grading systems.

□ — Grade A, □ — Grade B, □ — Grade C.

METHODS

Included in this series were 48 consecutive patients who underwent removal of their submandibular glands for sialolithiasis. The diagnosis of sialolithiasis was confirmed in all patients by conventional radiography, sialography, or ultrasound.

The indication for submandibular gland removal was 1) recurrent infections lasting more than 6 months or 2) chronic infection with symptoms lasting longer than 1 month despite antibiotic therapy. The surgery was performed under general anesthesia by standard techniques. For all patients, the following clinical data were noted: age, duration of symptoms, number of infectious episodes, time since the previous infection, and the surgery performed. By duration of

symptoms, we mean the delay between the first episode of inflammation of the gland and the operation. By number of infectious episodes, we mean only the swelling episodes treated with antibiotics, excluding transitory episodes of inflammatory swelling.

The removed submandibular glands were fixed in formalin before examination by the pathologist. For each gland, 8 slides were stained with hematoxylin and eosin. For each specimen, the degrees of inflammation, fibrosis, and atrophy were staged by the same pathologist (A.-M.K.) without knowledge of the clinical data. The degree of inflammation was classified into 1 of 3 grades (0 = absent, 1 = moderate, 2 = important). The degree of fibrosis underwent similar staging (from 0 to 2), and the location of the fibrosis was recorded (pericanalar or intralobular). The atrophy was classified as focal or diffuse and scored similarly (0 = no atrophy, 1 = focal atrophy, 2 = diffuse atrophy). Other pathological findings recorded include ectasia of intercalated ducts, granulomas, abscesses, presence of calciform cells, and squamous metaplasia of the ductal epithelium.

From these pathological findings, a new classification was established (Table 1 and Fig 1):

1. Grade A: no atrophy and no fibrosis (score 0), and absent or moderate inflammation (score 0 or 1).
2. Grade B: moderate atrophy (score 1) and/or fibrosis (score 1) with any stage of inflammation (score 0 to 2).
3. Grade C: important atrophy and/or fibrosis (score 2) with any stage of inflammation (score 0 to 2).

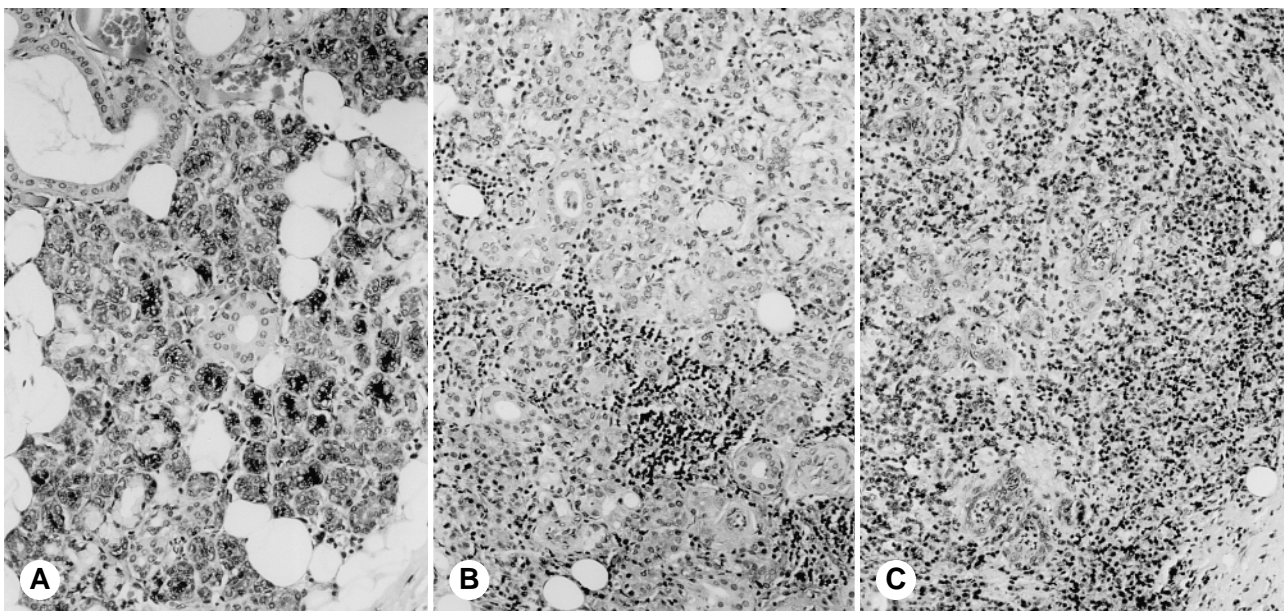


Fig 1. Histopathology of 3 pathological grades (H & E, original $\times 200$). **A)** Grade A. Normal glandular parenchyma. Absence of inflammation or atrophy. **B)** Grade B. Salivary gland shows moderate inflammatory infiltrate without significant atrophy. **C)** Grade C. Severely inflamed glandular parenchyma with microabscesses and diffuse atrophy.

TABLE 2. COMPARISON OF CLINICAL DATA OF PATIENTS BY HISTOLOGIC GRADE

<i>Clinical Parameters</i>	<i>Grade A</i>	<i>Grade B</i>	<i>Grade C</i>	<i>p</i>	<i>Total</i>
No. of patients	10	18	20		48
Age (y)	35.2 ± 16.6	36.7 ± 10.4	54.3 ± 17.6	.001	43.8 ± 17.3
No. of infectious episodes	3.4 ± 1.8	3.4 ± 1.7	3.4 ± 2.3	.99	3.4 ± 1.9
Duration of symptoms (y)	2.4 ± 1.4	3.4 ± 4.8	2.5 ± 4.1	.72	2.8 ± 3.4
Time between last episode and surgery (d)	64.5 ± 26.5	74.8 ± 89.3	73.8 ± 86.7	.94	72.2 ± 77.9

Data are mean values ± SD. See text for definition of grades.

The statistical association between pathological variables and clinical data was performed by 1-way analysis of variance.

RESULTS

The mean age of the 48 patients was 43.8 ± 17.3 (SD) years. On average, these patients experienced symptoms for 2.8 ± 3.4 years, the number of infectious episodes was 3.4 ± 1.9, and the frequency of episodes per year was 3.2 ± 3.6 (Table 2).

The histopathologic grading classified the submandibular gland specimens as grade A (n = 10), grade B (n = 18), or grade C (n = 20). The distribution of the averages of patient age and duration and number of infectious episodes according to histopathologic grade is shown in Table 2. Only the patient's age was significantly related to a more pathologically altered gland. The numbers of infectious episodes presented by the patient before the extirpation of the gland were similar (mean, 3.4) in all 3 groups. There was no significant difference in duration of symptoms among the 3 pathological groups. Similarly, there was no difference in the delay between the last infection and the surgery.

The statistical relationship between individual histopathologic variables and the clinical data is shown

TABLE 3. STATISTICAL CORRELATION BETWEEN CLINICAL COURSE AND DIFFERENT PATHOLOGICAL VARIABLES

<i>Pathological Variable</i>	<i>Age</i>	<i>No. of Episodes</i>	<i>Duration of Symptoms</i>	<i>Time Between Last Episode and Surgery</i>
Atrophy score	.01*	.46	.71	.46
Fibrosis score	.001*	.84	.97	.85
Inflammation score	.04*	.92	.32	.62
Focal atrophy	.55	.71	.49	.84
Diffuse atrophy	.02*	.78	.50	.47
Local fibrosis	.046*	.31	.39	.33
Periductal fibrosis	.041*	.93	.74	.49
Abscess	.55	.73	.32	.01*
Metaplasia	.10*	.16	.11	.02*

Data are p values.
*p ≤ 0.1.

in Table 3. None of the clinical data were significantly correlated to the pathological findings, except the patient's age. In particular, the 2 pathological variables most probably related to an impaired gland function, namely, diffuse atrophy and intralobular fibrosis, were associated with a similar number of infectious episodes and a similar duration of symptoms (Fig 2) as found in the cases without diffuse atrophy or intralobular fibrosis.

The delay between the last infectious episode and the surgery was inversely related ($p < .02$) to the presence of abscesses and metaplasia (Table 3). When a delay of 30 days was used to subdivide patients into 2 groups (18 patients with a delay of less than 30 days as compared with the 30 remaining patients), the 18 patients with a shorter delay had a statistically ($p < .05$) higher degree of inflammation (1.56 ± 0.5 versus 1.07 ± 0.22).

DISCUSSION

The same pathologist analyzed 48 submandibular glands removed for radiologically proven sialolithiasis. A classification into 1 of 3 histopathologic grades was established. Submandibular glands classified as grade A had normal histologic findings and were found in 10 of 48 cases. Grade C, corresponding to markedly altered histologic findings with extensive atrophy and fibrosis, was found in 20 glands. Grade B was a group of 18 cases with intermediate histologic alterations.

Although the patients in group A had normal histologic findings, they presented a clinical evolution similar to that of the patients in the other groups. In particular, their number of infectious episodes and their duration of symptoms were similar to those of the remaining patients, who had histologically altered glands. Therefore, on the basis of clinical symptoms, their submandibular gland removal was completely justified, considering that no precise criteria for submandibular gland removal in cases of sialolithiasis are available.

The only other pathological classification of submandibular glands affected by sialolithiasis was proposed by Seifert¹⁶ and modified by Isacson et al.¹⁴ Their grading was based mainly on the degree of in-

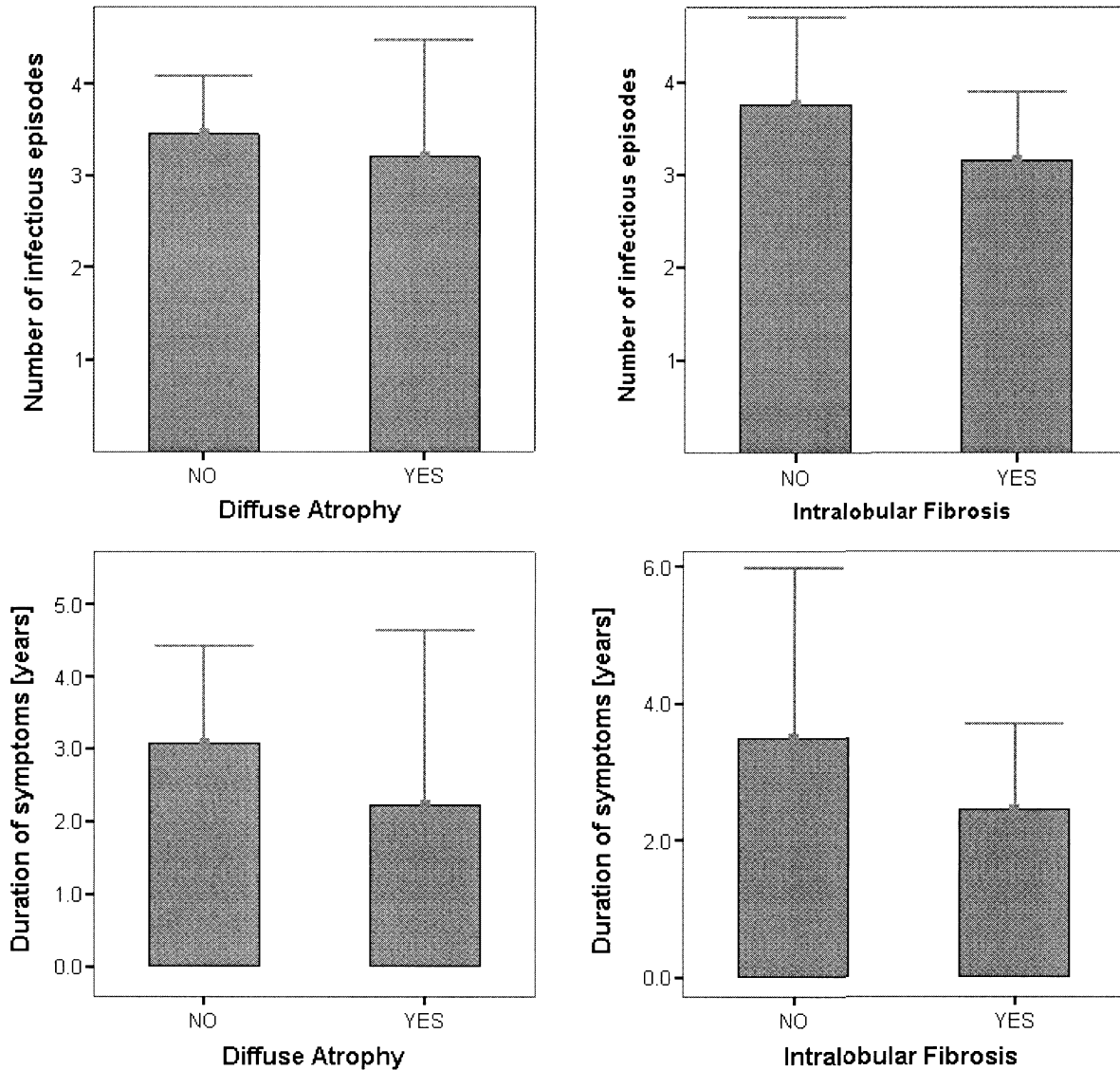


Fig 2. Presence or absence of fibrosis and atrophy correlated to clinical course.

flammation. In our study, the degree of inflammation was correlated to the delay between the last infectious episode and the surgery. Patients who suffered from chronic infectious processes and were operated on early had a significantly greater degree of inflammation than the remaining patients. Therefore, inflammation could be partially reversible, and does not obligatorily entail a permanent glandular dysfunction. Fibrosis and atrophy, such as considered in our grading, might be better predictors of the function of the gland. In the normal group (grade A), the glandular structure is completely conserved, and thus, we tend to assume that the function of the gland is normal. In the pathological group (grade C), most glandular acini were replaced by atrophy and/or fibrosis, and it is logical to postulate that the function of such glands is impaired. In the intermediate group (group B), there were no definitive signs by which to evalu-

ate the associated salivary function.

In our study, the clinical history in terms of number of infectious episodes and duration of symptoms was not correlated to the histopathologic grade. Therefore, numerous infectious episodes or a long duration of symptoms cannot be used to predict the histologic alteration of submandibular glands removed for sialolithiasis. Although there is no proof of a direct correlation between histologic findings and function, the common opinion that submandibular glands with sialolithiasis should be removed because they are nonfunctional should be revised.

Despite an abundant literature on the role of saliva,¹⁷ few specific tests of the function of an individual salivary gland are available. One possible approach is to evaluate the salivary flow. Van den Akker and Busemann-Sokole⁴ performed scintigraphic and

salivary secretion tests on patients after unilateral transoral removal of sialolithiasis. In their study, the majority of operated submandibular glands exhibited an output comparable to that of the normal contralateral submandibular gland. Already, in 1983, they had concluded that "the presence of a stone at the knee of the submandibular duct does not necessarily warrant excision of the submandibular gland."^{4(p356)}

The only clinical variable that was correlated with the histopathologic grading was the patient's age. Scott¹⁸ analyzed the histologic changes in submandibular glands obtained at necropsy of patients from 16 to 95 years old. Glands retrieved from young patients had a compact parenchyma, interrupted with thin fibrous bands, whereas older glands exhibited acinar atrophy and increased pericanalar fibrosis. Although a correlation to the commonly observed decrease of salivary function in elderly patients remains speculative, Scott's results are similar to our observations.

All of our patients had a lithiasis, proven not only by conventional radiologic techniques but also by ultrasound and magnetic resonance sialography.¹⁹ Seifert and Donath,²⁰ in 1977, in a survey of 349 extirpated glands with sialadenitis, found only 41% of stones by conventional radiology. Isacson et al¹⁴

found 84% of stones by pathology in their series of submandibular glands resected for sialadenitis. The exact pathogenesis of sialadenitis remains unclear.² Recent advances in diagnostic imaging¹⁹ and diagnostic sialendoscopy²¹⁻²³ make us favor sialolithiasis as the main cause of nonspecific sialadenitis. Conservative techniques for removal of sialolithiasis, such as external lithotripsy²⁴⁻²⁶ and intraductal lithotripsy,²⁷⁻²⁹ have already proven their efficacy. New endoscopic techniques, such as endoscopic-assisted stone removal, are being developed and may be of interest in the near future.²¹⁻²³

CONCLUSIONS

1. A new histopathologic grading of submandibular glands removed for sialolithiasis is proposed.
2. A significant percentage of submandibular glands removed for sialolithiasis exhibit normal histologic characteristics.
3. The patients with normal submandibular glands have a clinical evolution similar to that of other patients with severely damaged glands.
4. In view of the newly available diagnostic and therapeutic techniques for sialolithiasis, a conservative attitude to submandibular gland resection appears justified.

REFERENCES

1. Lustmann J, Regev E, Melamed Y. Sialolithiasis. A survey on 245 patients and a review of the literature. *Int J Oral Maxillofac Surg* 1990;19:135-8.
2. Cawson RA, Gleeson MJ, Eveson JW. Sialadenitis. In: Cawson RA, Gleeson MJ, Eveson JW, eds. *Pathology and surgery of the salivary glands*. Oxford, England: Isis Medical Media, 1997:33-63.
3. Rice DH. Diseases of the salivary glands — non-neoplastic. In: Bailey B, Pillsbury HC, eds. *Head and neck surgery—otolaryngology*. Philadelphia, Pa: JB Lippincott, 1993:475-84.
4. van den Akker HP, Busemann-Sokole E. Submandibular gland function following transoral sialolithectomy. *Oral Surg Oral Med Oral Pathol* 1983;56:351-6.
5. Crabtree GM, Yarrington CT. Submandibular gland excision. *Laryngoscope* 1988;98:1044-5.
6. Hald J, Koks-Andreassen U. Submandibular gland excision: short- and long-term complications. *ORL J Otorhinolaryngol Relat Spec* 1994;56:87-91.
7. Goh YH, Sethi DS. Submandibular gland excision: a five-year review. *J Laryngol Otol* 1998;112:269-73.
8. Smith WP, Peters WJ, Markus AF. Submandibular gland surgery: an audit of clinical findings, pathology and postoperative morbidity. *Ann R Coll Surg Engl* 1993;75:164-7.
9. Berini-Aytes L, Gay-Escoda C. Morbidity associated with removal of the submandibular gland. *J Craniomaxillofac Surg* 1992;20:216-9.
10. Coumel C, Vesse M, Perrin L, Rouaux JP. 50 Sous-maxillectomies. *Rev Stomatol Chir Maxillofac* 1979;80:344-8.
11. Panzoni E, Marchesi A, Lippi L. Sialoadenectomia sottomandibolare: tecniche chirurgiche, casistica operatoria ed esiti a distanza. *Riv Ital Stomatol* 1984;53:121-30.
12. Milton CM, Thomas BM, Bickerton RC. Morbidity study of submandibular gland excision. *Ann R Coll Surg Engl* 1986;68:148-50.
13. Isacson G, Lundquist PG. Salivary calculi as an aetiological factor in chronic sialadenitis of the submandibular gland. *Clin Otolaryngol* 1982;7:231-6.
14. Isacson G, Ahlner B, Lundquist PG. Chronic sialadenitis of the submandibular gland. A retrospective study of 108 cases. *Arch Otorhinolaryngol* 1981;232:91-100.
15. Shinohara M, Oka M, Yamada K, Hashimura K, Yuba K, Mori M. Immunohistochemical and electronmicroscopic studies of obstructive lesions in submandibular glands. *J Oral Pathol Med* 1992;21:370-5.
16. Seifert G. Klinische Pathologie der Sialadenitis und Sialadenose. *HNO* 1971;19:1-9.
17. Batsakis JG. Salivary glands. Physiology. In: Cummings CW, Fredrickson JM, Harker LA, Krause CJ, Schuller DE, eds. *Otolaryngology—head and neck surgery*. St Louis, Mo: Mosby, 1993:986-1007.
18. Scott J. Degenerative changes in the histology of the human submandibular salivary gland occurring with age. *J Biol Buccale* 1977;5:311-9.
19. Becker M, Marchal F, Becker CD, et al. Sialolithiasis and salivary ductal stenosis: diagnostic accuracy of MR sialography with a three-dimensional extended-phase conjugate-sym-

metry rapid spin-echo sequence. *Radiology* 2000;217:347-58.

20. Seifert G, Donath K. Zur Pathogenese des Kutter-Tumors der Submandibularis. Analyse von 349 Fallen mit chronischer Sialadenitis der Submandibularis. *HNO* 1977;25:81-92.

21. Marchal F, Becker M, Dulguerov P, Lehmann W. Interventional sialendoscopy. *Laryngoscope* 2000;110:318-20.

22. Marchal F, Dulguerov P, Becker M, Lehmann W. Interventional sialendoscopy. In: Wackym PA, Rice DH, Schaefer SD, eds. Minimally invasive surgery of the head, neck and cranial base. Philadelphia, Pa: Lippincott, Williams & Wilkins (in press).

23. Marchal F, Dulguerov P, Lehmann W. Interventional sialendoscopy. *N Engl J Med* 1999;341:1242-3.

24. Katz P. Thérapeutiques non chirurgicales des lithiases salivaires. Endoscopie et lithotripsie extra-corporelle. *Rev Off*

Soc Fr ORL 1997;45:47-52.

25. Iro H, Schneider HT, Fodra C, et al. Shockwave lithotripsy of salivary duct stones. *Lancet* 1992;339:1333-6.

26. Kater W, Meyer WW, Wehrmann T, Hurst A, Buhne P, Schlick R. Efficacy, risks, and limits of extracorporeal shock wave lithotripsy for salivary gland stones. *J Endourol* 1994;8:21-4.

27. Gundlach P, Scherer H, Hopf J, et al. Die endoskopisch kontrollierte Laserlithotripsie von Speichelsteinen. In-vitro-Untersuchungen und erster klinischer Einsatz. *HNO* 1990;38:247-50.

28. Arzoz E, Santiago A, Esnal F, Palomero R. Endoscopic intracorporeal lithotripsy for sialolithiasis. *J Oral Maxillofac Surg* 1996;54:847-52.

29. Ito H, Baba S. Pulsed dye laser lithotripsy of submandibular gland salivary calculus. *J Laryngol Otol* 1996;110:942-6.