

Nasal and Paranasal Sinus Carcinoma: Are We Making Progress?

A Series of 220 Patients and a Systematic Review

Pavel Dulguerov, M.D., Ph.D.^{1,2}

Michael S. Jacobsen, M.D.¹

Abdelkarim S. Allal, M.D.³

Willy Lehmann, M.D.²

Thomas Calcaterra, M.D.¹

¹ Division of Head and Neck Surgery, Department of Surgery, University of California-Los Angeles, Los Angeles, California.

² Division of Head and Neck Surgery, Geneva University Hospital, Geneva, Switzerland.

³ Division of Radio-Oncology, Geneva University Hospital, Geneva, Switzerland.

Presented at the fifth International Conference on Head and Neck Cancer, San Francisco, California, August, 2000.

Address for reprints: Pavel Dulguerov, M.D., Ph.D., Division of Head and Neck Surgery, Geneva University Hospital, 24, rue Micheli-du-Crest, 1205 Geneva, Switzerland; Fax: (+4122) 372 8240; E-mail: pavel.dulguerov@hcuge.ch

Received March 27, 2001; revision received July 25, 2001; accepted August 30, 2001.

BACKGROUND. The authors reviewed treatment results in patients with nasal and paranasal sinus carcinoma from a large retrospective cohort and conducted a systematic literature review.

METHODS. Two hundred twenty patients who were treated between 1975 and 1994 with a minimum follow-up of 4 years were reviewed retrospectively. A systematic review of published articles on patients with malignancies of the nasal and paranasal sinuses during the preceding 40 years was performed.

RESULTS. The 5-year survival rate was 40%, and the local control rate was 59%. The 5-year actuarial survival rate was 63%, and the local control rate was 57%. Factors that were associated statistically with a worse prognosis, with results expressed as 5-year actuarial specific survival rates, included the following: 1) histology, with rates of 79% for patients with glandular carcinoma, 78% for patients with adenocarcinoma, 60% for patients with squamous cell carcinoma, and 40% for patients with undifferentiated carcinoma; 2) T classification, with rates of 91%, 64%, 72%, and 49% for patients with T1, T2, T3, and T4 tumors, respectively; 3) localization, with rates of 77% for patients with tumors of the nasal cavity, 62% for patients with tumors of the maxillary sinus, and 48% for patients with tumors of the ethmoid sinus; 4) treatment, with rates of 79% for patients who underwent surgery alone, 66% for patients who were treated with a combination of surgery and radiation, and 57% for patients who were treated exclusively with radiotherapy. Local extension factors that were associated with a worse prognosis included extension to the pterygomaxillary fossa, extension to the frontal and sphenoid sinuses, the erosion of the cribriform plate, and invasion of the dura. In the presence of an intraorbital invasion, enucleation was associated with better survival. In multivariate analysis, tumor histology, extension to the pterygomaxillary fossa, and invasion of the dura remained significant. Systematic review data demonstrated a progressive improvement of results for patients with squamous cell and glandular carcinoma, maxillary and ethmoid sinus primary tumors, and most treatment modalities.

CONCLUSIONS. Progress in outcome for patients with nasal and paranasal carcinoma has been made during the last 40 years. These data may be used to make baseline comparisons for evaluating newer treatment strategies. *Cancer* 2001;92:3012-29. © 2001 American Cancer Society.

KEYWORDS: carcinoma, nose, paranasal sinus, multivariate, meta-analysis.

Malignancies of the nasal cavity and paranasal sinuses are rare neoplasms that account for only 3% of head and neck carcinomas and about 0.5% of all malignant diseases. The annual incidence rate is 0.5-1.0 per 100,000 population.^{1,2} This small incidence rate and the great variety of histologic types³ explain the fact that few centers have had extensive experience with the treatment of patients with

these tumors.⁴⁻⁷ Furthermore, the complexity of the anatomy and the proximity of the eye, brain, and cranial nerves render radical surgery⁸⁻¹⁰ and radiation therapy¹¹⁻¹³ delicate, and such treatments are associated with numerous complications. Although the first resections of the maxilla were described nearly 200 years ago,¹⁴ surgical treatment of nasal and paranasal carcinomas remained for a long time a piecemeal extirpation associated with a high rates of recurrence and low success rates.¹⁵ The results obtained during that period are well illustrated in two publications from the Memorial Hospital^{16,17}: In 677 patients who were treated over the preceding 30 years with radiation (20%) or surgery (80%), the global cure rate was 28%. Similar results can be found in radiation therapy series from the same period.^{18,19}

Although several studies have underlined the lack of improvement in disease mortality,²⁰ we hypothesized that advancements within the last decades may have resulted in improved survival for patients with nasal and paranasal carcinoma. Progress in treatment modalities for these patients during the last 30 years include more extensive and radical base-of-skull surgical procedures²¹⁻²⁴; the use of treatments combining surgery and radiotherapy; developments in radiation therapy, such as hyperfractionation,²⁵ better field delineation by three-dimensional dosimetry,²⁵⁻²⁷ and proton therapy²⁶; as well as better preoperative assessment of the extent of disease by imaging modalities.²⁸

We present a retrospective review of 220 patients with carcinoma of the nasal cavity and paranasal sinuses who were treated at two institutions during the preceding 20 years. A systematic review of the literature also was conducted to determine whether any improvement in treatment results was achieved during the last 40 years. Data from patient subgroups divided by such factors as tumor histology, tumor sites, and treatment modalities may be used as a reference for future developments.

MATERIALS AND METHODS

Patients

A retrospective chart review was conducted of patients who were treated for carcinoma of the nasal cavity and paranasal sinuses at two centers: the University of California-Los Angeles and the University Hospital of Geneva, Switzerland. The study period spanned 20 years from January 1975 to December 1994.

Inclusion criteria

Patients with benign tumors, such as inverted papilloma, and with palate or skin primary tumors with secondary invasion of the sinuses and nose were excluded. Patients with nasal vestibule primary tumors

also were excluded, because these tumors probably are related more to skin primary tumors than to nasal carcinoma. Only patients who were treated primarily and who had a minimal follow-up of 4 years were included. The data collected include the age and gender of patients; the side, site, and T classification of the primary tumor; tumor histology; the adjacent structures involved; the treatment modalities used; the possible recurrences and their treatment; and survival data.

Site and staging

The tumor site was determined from the epicenter of the disease, as determined at the time of diagnosis or, more rarely, from an analysis of the clinical, radiologic, or operative data. The sites considered were the maxillary sinus, the ethmoid sinus, the sphenoid sinus, the frontal sinus, and the nasal cavity.²⁹ For each site, the invasion of each adjacent anatomic structure was noted and analyzed separately.

Patients who were not classified at the time of diagnosis according to the International Union Against Cancer (UICC) TNM classification system³⁰ for malignancies of the maxillary or ethmoid sinuses were reclassified retrospectively by reevaluating the clinical and radiologic data. Because of the low incidence of sphenoid and frontal primary tumors, these were analyzed with the primary tumors of the ethmoid sinus and were grouped with advanced (T4) primary tumors of the ethmoid sinus. Nasal cavity primary tumors were reclassified retrospectively according to the 1993 UICC classification system.²⁹ Nonsquamous cell primary tumors were assigned a T classification by analogy to a similar squamous cell carcinoma.

Histology

The tumors were divided in four histologic groups: squamous cell carcinoma (squamous cell, transitional, and verrucous), adenocarcinoma, glandular carcinoma (adenoid cystic carcinoma and mucoepidermoid carcinoma), and undifferentiated carcinoma.

Treatment

Treatment consisted of surgery, radiation, chemotherapy, or various combinations of these modalities. In the absence of clinical and radiologic evidence of cervical lymph node involvement, no prophylactic treatment was administered to the neck. Surgical resections were grouped into six types: inferior, median, or total maxillectomy; orbital exenteration; craniofacial resection; and infratemporal fossa resection. Depending on the extent of disease, a combination of these different surgeries was used.

Radiotherapy was administered with daily doses

of 1.8–2.0 grays (Gy) 5 days per week for a total dose of 60–65 Gy. The technique used most often combined one anterior field and two lateral fields of Co⁶⁰ gamma photons or 6 MV photons X. Until 1991, the irradiation isodoses were determined by conventional dosimetry techniques; since then, computed tomography-based, three-dimensional dosimetry, determined in the treatment position, has allowed for better mapping of the target volume and aims to preserve the surrounding structures. The chemotherapy regimen used for most patients was a combination of cisplatin and 5-fluorouracil.

Patient Data: Statistical Analysis

Results were analyzed in terms of actuarial local control and survival according to the Kaplan–Meier product limit method. Survival and local control profiles were examined for univariate statistical differences using the log-rank test. Multivariate survival analysis was performed with the Cox proportional hazards method. The statistical analysis software used was SPSS (version 9.0; SPSS, Inc., Chicago, IL).

Systematic Review

Hypothesis

The main hypothesis of this systematic review^{31–33} was that the survival of patients with nasal and paranasal carcinoma has improved over the last 40 years. A secondary hypothesis was that differences in survival would be found in histology, disease site, stage, and treatment subgroups.

Literature search and article selection

The MEDLINE data base was searched from 1960 to 1999 with a Boolean combination (nasal carcinoma or paranasal carcinoma *and* treatment). To locate recent articles not yet indexed in MEDLINE, the current content issues for the last 3 months of 1999 were reviewed. The search was supplemented by cross checking the references in each article, a strategy responsible for 30% of all references included. Two investigators conducted the search independently.

To be included, articles had to present results from the treatment of patients with carcinoma of the nasal fossa and/or one of the paranasal sinuses. Articles that reported on patients with primary tumors of the nasal vestibule were excluded for the reasons discussed above. Articles with a population of fewer than 20 patients were excluded, because they often represented case reports or studies on experimental treatments, or they originated from centers with small recruitment and, thus, possibly insufficient experience. In addition, articles with unclear follow-up or with minimal follow-up (< 2 years) were excluded. Numer-

ous articles reported treatment results for patients with tumors of mixed histology, not only carcinoma: To be included, at least two-thirds of the patients' histology in a given article had to be carcinoma. In these articles, only data specifically addressing the outcome of patients with carcinoma were tabulated. Several centers have published recurrently on this subject^{34–58} and, most probably, on similar (if not identical) patients. We arbitrarily decided to include one article per 5-year period unless the focus of study clearly was different. Finally, only articles in five languages (English, French, German, Italian, and Spanish) were selected. No contacts were made with individual authors, and no effort was made to look for unpublished studies.³³

Data extraction

The treatment results from each article selected were extracted and grouped into five categories: global, site of the primary tumor, histology, T classification, and treatment modality. The definitions for each category were similar to those described for our patients. Chemotherapy was used rarely (5% of patients), and, to provide a population of sufficient size, patients who received the various combined treatments, including chemotherapy, were grouped together. Because few studies used a T classification for tumors of the nasal cavity and ethmoid sinus, only T classification data for the maxillary sinus were collected. In addition, the lymph node status and the sites of recurrence were analyzed.

Few studies provided clear data in all categories: Some studies provided only global results, others provided only site specific results, etc. In each publication, the available data were collected and expressed as a percent of the population treated for each category; thus, studies with larger numbers of patients carried more weight in the category average. When available, 5-year actuarial survival data were used; otherwise, 5-year crude survival data were collected.

Data extraction was performed independently by two investigators, and any difference was reconciled through discussions. No blinding of the authors or institution for individual articles was carried out.⁵⁹ Although it is obvious that the quality of the individual articles differed substantially, we decided against rating article quality because of the lack of an accepted scale for oncology articles and the uncertain benefit of the process.⁵⁹

Statistical analysis

For each of the five categories, the available data were grouped according to the year of publication in four decades: 1960s, 1970s, 1980s, and 1990s. The treat-

ment results were expressed as a 5-year survival average and standard deviation for each variable. Because data for most of these groups did not follow a normal distribution, more conservative nonparametric tests were used (the Kruskal–Willis test for independent samples, as implemented by SPSS software; version 9.0). It seemed obvious that the studies analyzed were heterogeneous; thus, no heterogeneity or sensitivity tests were performed.^{33,59}

RESULTS

From 1975 to 1995, 386 patients with carcinoma of the nasal cavity and paranasal sinuses were diagnosed and treated at both institutions: 74 patients in Geneva and 312 patients at the University of California–Los Angeles. Patients with disease types other than carcinoma, such as lymphoma ($n = 38$ patients), melanoma ($n = 34$ patients), sarcoma ($n = 52$ patients), and esthesioneuroblastoma ($n = 42$ patients), were excluded. The remaining 220 patients with primarily treated nasal and paranasal carcinoma represent the study population. The minimal, average, and median follow-up were 48 months, 87 months, and 72 months, respectively.

The overall crude survival data show that 88 patients (40%) were alive without disease, 5 patients (2.3%) were alive with disease, there were 32 intercurrent deaths (14.5%), and 95 patients (43.2%) died of disease. Thus, 93 patients (42.3%) were alive, and 127 patients (57.7%) had died at the time of this report. The crude 5-year disease specific survival rate was 54.5% (120 patients). For the entire population, the actuarial overall survival rate was $75\% \pm 3\%$ at 2 years, $60\% \pm 3\%$ at 5 years, and $47\% \pm 4\%$ at 10 years. The carcinoma specific actuarial survival (CSAS) rate was $76\% \pm 3\%$ at 2 years, $63\% \pm 3\%$ at 5 years, and $56\% \pm 4\%$ at 10 years.

Disease recurrences or metastases were present in 114 patients (52%), whereas 106 patients (48%) never experienced disease recurrence. Local control was achieved in 129 patients (59%). The actuarial locoregional control (ALRC) rate was $67\% \pm 3\%$ at 2 years, $59\% \pm 3\%$ at 5 years, and $54\% \pm 4\%$ at 10 years.

Gender

Among 220 patients, 84 were female (38%), and 136 were male (62%). The 5-year ALRC rate was better in female patients ($69\% \pm 5\%$) compared with male patients ($53\% \pm 5\%$), and this difference was statistically significant ($P = 0.02$). The 5-year CSAS rate was $72\% \pm 5\%$ in female patients and $57\% \pm 4\%$ in male patients (not significant).

Age

The average age was 56.7 years \pm 14.8 years. The median age was 58 years (range, 9–86 years). Several age groupings were computed, but no statistical association between ALRC/CSAS and age could be found.

Side

The right side was involved in 100 patients (45.5%), the left side in 108 patients (49%), and the tumors were bilateral in 12 patients (5.5%). The ALRC rates at 5 years were $70\% \pm 5\%$, $53\% \pm 5\%$, and $25\% \pm 12\%$ for patients with right, left, and bilateral involvement, respectively ($P = 0.002$). The 5-years CSAS rates were $73\% \pm 5\%$, $57\% \pm 5\%$, and $30\% \pm 14\%$, for patients with right, left, and bilateral involvement, respectively ($P = 0.03$). This statistical difference persisted after patients with bilateral involvement were excluded.

Histology

Squamous cell carcinoma was the most frequent histologic type and was found in 126 patients (57.3%). There were 39 patients (17.7%) with glandular carcinoma, most of whom had adenoid cystic carcinoma (35 patients). There also were 25 patients (11.4%) with adenocarcinoma and 30 patients (13.6%) with undifferentiated carcinoma. The ALRC and CSAS rates for these four histologic groups are shown in Table 1. Adenocarcinoma and glandular carcinoma treatment results were the best, with a 5-year CSAS rate of $\approx 78\%$, followed by squamous cell carcinoma (60%) and undifferentiated carcinoma (40%). The Kaplan–Meier survival curves for the four histologic groups are shown in Figures 1 and 2. The log-rank test was significant for CSAS (0.001) but not for ALRC ($P = 0.06$).

Location

The site of origin was the maxillary sinus in 103 patients (47%), the nasal cavity in 66 patients (30%), the ethmoid sinus in 38 patients (17.3%), the sphenoid sinus in 7 patients (3.2%), and the frontal sinus in 2 patients (0.9%). For the analysis, patients with carcinoma of the sphenoid and frontal sinuses were grouped with patients with ethmoid sinus carcinoma and classified as T4. In 4 patients, the tumors were so large that the exact locus of origin could not be determined.

The ALRC and CSAS data for the four locations are shown in Table 2. Patients with carcinoma of the nasal cavity exhibited higher control and actuarial survival rates compared with the rates in patients with sinus carcinoma. In addition, the results for patients with maxillary carcinoma were better compared with the

TABLE 1
Actuarial Locoregional Control and Disease Specific Actuarial Survival Rates According to Histology

Histology	No. (%)	Survival (%)			P value
		Two years	Five years	Ten years	
ALRC					
Squamous cell carcinoma	126 (57.3)	61 ± 4	58 ± 5	56 ± 5	—
Glandular carcinoma	39 (17.7)	79 ± 0.07	68 ± 8	54 ± 9	—
Adenocarcinoma	25 (11.4)	84 ± 7	69 ± 10	63 ± 11	—
Undifferentiated carcinoma	30 (13.6)	57 ± 9	41 ± 10	33 ± 11	0.06
CSAS					
Squamous cell carcinoma	126 (57.3)	73 ± 4	60 ± 5	59 ± 5	—
Glandular carcinoma	39 (17.7)	87 ± 5	79 ± 6	64 ± 8	—
Adenocarcinoma	25 (11.4)	92 ± 5	78 ± 9	72 ± 10	—
Undifferentiated carcinoma	30 (13.6)	60 ± 9	40 ± 9	24 ± 9	0.001

ALRC: actuarial locoregional control; CSAS: carcinoma specific actuarial survival.

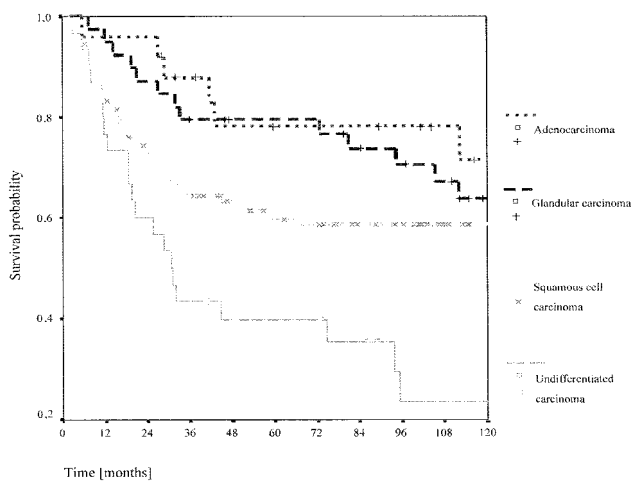


FIGURE 1. Disease specific survival probability according to histology in 220 patients with nasal and paranasal sinus carcinoma.

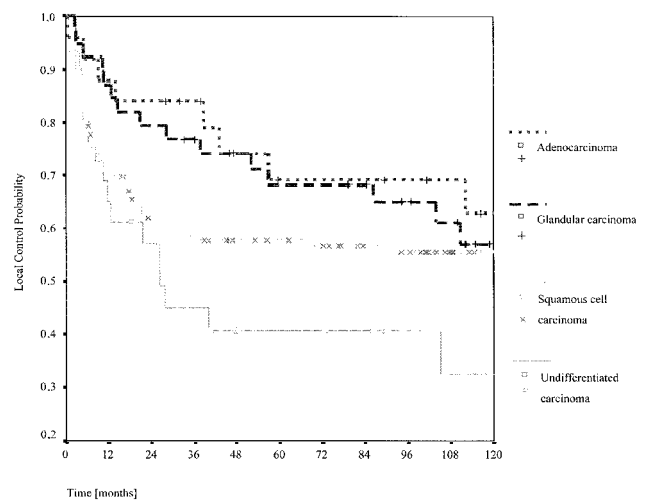


FIGURE 2. Probability of locoregional control according to histology in 220 patients with nasal and paranasal sinus carcinoma.

results for patients with carcinoma of the ethmoid sinus. A log-rank comparison of the ALRC and CSAS profiles (Fig. 3) was highly significant ($P = 0.001$).

The distribution of location according to tumor histology is presented in Table 3. Squamous cell carcinoma was the most frequent histology in all sites. In the maxilla, the next most frequent histology was glandular carcinoma (26%), whereas patients with adenocarcinoma outnumbered patients with glandular carcinoma in the ethmoid sinus (34% vs. 9%). Undifferentiated carcinoma represented between 10% and 17% of carcinoma in the three locations.

Stage

The distribution by T classification was 25 patients (11.4%) with T1 tumors, 51 patients (23.2%) with T2 tumors, 52 patients (23.6%) with T3 tumors, and 92

patients (41.8%) with T4 tumors. A cross tabulation by T classification, histology, and location is presented in Table 3. The majority of patients ($\approx 70\%$) with squamous cell carcinoma and undifferentiated carcinoma had T3–T4 tumors, whereas patients with glandular carcinoma were distributed more evenly across T classifications. Large numbers of patients had T3–T4 carcinoma of the maxillary sinus (80%) and the ethmoid sinus (79%), whereas, among patients with carcinoma of the nasal cavity, only 22% had T3–T4 tumors.

The 5-year CSAS rates (Fig. 4) were $92\% \pm 6\%$, $64\% \pm 7\%$, $72\% \pm 6\%$, and $49\% \pm 5\%$ for patients with T1, T2, T3, and T4 tumors, respectively, and the respective 5-year ALRC rates were $79\% \pm 9\%$, $62\% \pm 7\%$, $67\% \pm 7\%$, and $48\% \pm 5\%$. Although the difference between T2 and T3 tumors was not obvious, the overall log-

TABLE 2
Actuarial Locoregional Control and Disease Specific Actuarial Survival Rates According to the Location of Nasal and Paranasal Sinus Carcinoma

Location	No. (%)	Survival (%)			P value
		Two years	Five years	Ten years	
ALRC					
Maxillary sinus	103 (46.8)	66 ± 5	61 ± 5	51 ± 6	—
Ethmoid sinus	47 (21.4)	57 ± 7	44 ± 7	41 ± 7	—
Nasal cavity	66 (30)	77 ± 5	71 ± 6	71 ± 6	—
Sinus NOS	4 (1.8)	25 ± 22	0	0	> 0.001
CSAS					
Maxillary sinus	103 (46.8)	73 ± 4	62 ± 5	52 ± 5	—
Ethmoid sinus	47 (21.4)	66 ± 7	48 ± 7	46 ± 7	—
Nasal cavity	66 (30)	88 ± 4	77 ± 5	75 ± 6	—
Sinus NOS	4 (1.8)	75 ± 22	25 ± 22	0	0.001

ALRC: actuarial locoregional control; CSAS: carcinoma specific actuarial survival; NOS: not otherwise specified.

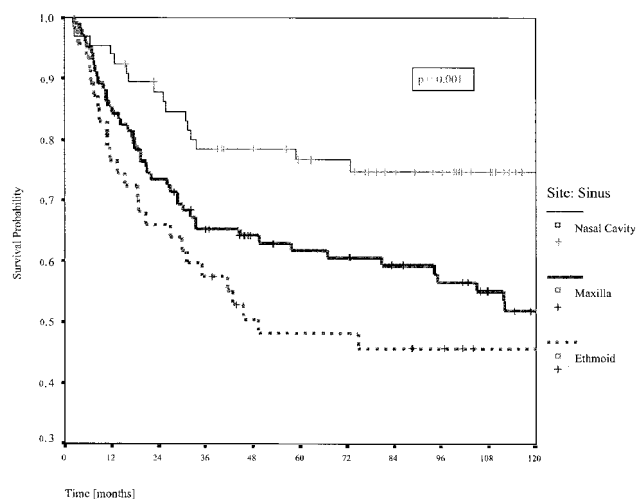


FIGURE 3. Disease specific survival probability according to tumor location in 216 patients with nasal and paranasal sinus carcinoma.

rank test was significant for both the CSAS rate ($P = 0.0001$) and the ALRC rate ($P = 0.005$).

Treatment

Surgery was performed in 156 patients (71%) either as the sole treatment modality (43 patients; 19.5%) or combined with radiation therapy (102 patients; 46.4%). Radiation therapy alone administered to 45 patients (20.5%). Chemotherapy was administered to 30 patients (13.6%): alone in 2 patients, with surgery in 1 patient, with surgery and radiotherapy in 11 patients (5%), and with radiation in 16 patients (7.3%). Because of the small numbers of patients who were treated with chemotherapy, patients were grouped according to surgery and/or radiotherapy regimens for further data analysis as follows: surgery alone (44 patients;

20%), surgery and radiation (113 patients; 51%), and radiation alone (61 patients; 28%).

In general, radiation therapy or a combination of surgery and radiation seem to have been used in patients who had less favorable outcomes: those with undifferentiated carcinoma, primary tumors of the ethmoid and maxillary sinuses, and T3–T4 tumors (Table 4). A chi-square test of the distribution of treatment modality by histology ($P = 0.006$), location ($P < 0.001$), and stage ($P < 0.001$) confirmed that the choice of treatment modality was not random.

For patients who underwent surgery alone, surgery and radiation, and radiotherapy alone, the ALRC and CSAS rates are presented in Table 5. The 5-year ALRC and CSAS rates were better for patients who underwent surgery alone (70% and 79%, respectively) and for patients who underwent a combination of radiotherapy and surgery (64% and 66%, respectively) compared with patients who underwent radiotherapy alone (44% and 46%, respectively). The log-rank test comparison of CSAS data (Fig. 5) and ALRC data was significant ($P < 0.01$).

Metastasis at Presentation

Only five patients (2.3%) had cervical lymph node metastasis at the time of diagnosis. Two of these five patients were classified with N1 status, and 3 patients were classified with N2 status. The histologies of primary tumors were squamous cell carcinoma in four patients and undifferentiated carcinoma in one patient. The tumors were classified as T3 tumors in two patients and T4 tumors in three patients. The primary tumor location was the maxillary sinus in three patients, the ethmoid sinus in one patient, and the nasal cavity in one patient. The results of a Fisher exact test

TABLE 3
Cross Tabulation of the Number of Patients by Histology, Site and T Classification^a

Histology	Maxillary sinus (%)					Ethmoid sinus (%)					Nasal cavity (%)					Total (%)
	T1	T2	T3	T4	Subtotal	T1	T2	T3	T4	Subtotal	T1	T2	T3	T4	Subtotal	
Squamous cell carcinoma	3	8	18	33	62 (60)	0	2	2	15	19 (40)	15	16	7	4	42 (63)	123 (57)
Glandular carcinoma	3	5	8	11	27 (26)	0	1	1	2	4 (9)	2	3	1	2	8 (12)	39 (18)
Adenocarcinoma	0	1	1	2	4 (4)	0	6	8	2	16 (34)	1	3	1	0	5 (8)	25 (12)
Undifferentiated carcinoma	0	1	5	4	10 (10)	0	1	0	7	8 (17)	1	4	0	6	11 (17)	29 (13)
Total	6 (6)	15 (15)	32 (31)	50 (48)	103 (48)	0 (0)	10 (21)	11 (23)	26 (54)	47 (22)	19 (29)	26 (39)	9 (14)	12 (18)	66 (30)	(100)

^a Four patients with sinus "not otherwise specified" histology were omitted. The subtotal columns show the numbers of patients for the histologies at each site, and the bottom total line shows the numbers of patients with tumors in each T classification for each site. The percentages for both are related to the total numbers of ●●● for each site.

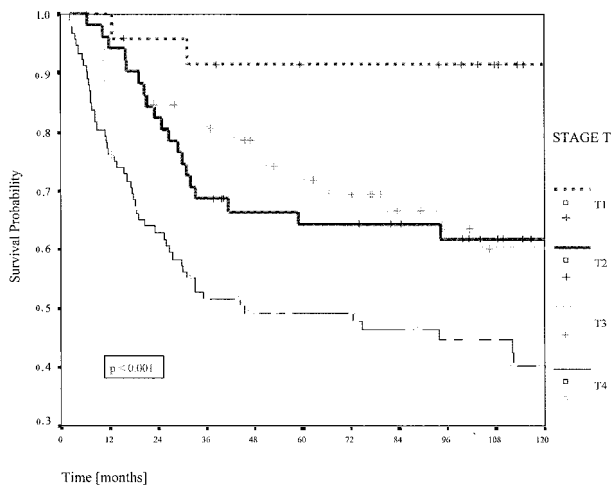


FIGURE 4. Disease specific survival probability according to T stage in patients with nasal and paranasal sinus carcinoma.

of the association of lymph node status with primary histology, stage, and location were not significant.

The locoregional control rate in patients with positive lymph nodes was 20% at 2 years. Only one patient was alive without disease 8 years after treatment. Although three of five patients did not experience disease recurrence in the neck, three patients presented with local recurrences, and one patient presented with distant metastases. Four patients (1.8%) presented with distant metastases at the time of diagnosis, and all died within 2 years.

Recurrences and Their Treatment

Disease recurrences were noted in 114 patients (51.3%), whereas 106 patients (48.7%) never presented a local, regional, or distant recurrence. In 11 patients (5%), the type of recurrence could not be determined

from the available data. The remaining 103 recurrences consisted of 73 patients (35%) with local recurrences; 4 patients (1.9%) with local and regional recurrences; 7 patients (3.3%) with local and distant metastases; 2 patients (1.9%) with local, regional, and distant metastasis; 8 patients (3.8%) with regional recurrences alone; and 9 patients (4.3%) with distant metastasis alone (Table 6). The total number of recurrences was 86 patients (41%) with local recurrences, 14 patients (6.7%) with regional recurrences, and 18 patients (8.1%) with distant metastasis. When the primary tumor was controlled, only 10 patients (4.8%) presented with regional recurrences, and 11 patients (5.3%) presented with distant metastasis.

A salvage treatment was successful in 11 of 86 patients (13%) with local recurrences and in 3 of 14 patients (21%) with regional recurrences. Because 9 patients had only distant metastasis, locoregional control was obtained in 129 patients (59%).

The remaining 75 patients with local recurrences are either dead ($n = 73$ patients) or alive with disease ($n = 2$ patients). The remaining 11 patients with regional recurrences all are dead. There was no statistical association (chi-square test) between regional recurrence and histology ($P = 0.6$), T classification ($P = 0.4$), location of the primary tumor ($P = 0.8$), or treatment modality ($P = 0.8$).

Local Extensions and Local Control

Because local failure is the most frequent type of recurrence, all possible local extension sites were examined in an attempt to find an association with local recurrence. Among the sites surrounding the maxilla, only patients with an extension to the pterygomaxillary fossa ($P = 0.02$) had a significantly worse prognosis. For the sites surrounding the ethmoid sinus, pa-

TABLE 4
Cross Tabulation of Treatment Modality by Histology, Site, and T Classification^a

Characteristic	Surgery (%)	Surgery and radiotherapy (%)	Radiotherapy (%)	Total (%)
Global	44 (20)	113 (52)	61 (28)	218 (100)
Histology				
Squamous cell carcinoma	32 (26)	56 (45)	37 (30)	125 (57)
Glandular carcinoma	8 (21)	22 (56)	9 (23)	39 (18)
Adenocarcinoma	4 (16)	18 (72)	3 (12)	25 (12)
Undifferentiated carcinoma	0 (0)	17 (59)	12 (41)	29 (13)
Location				
Maxillary sinus	17 (17)	59 (58)	26 (25)	102 (46.8)
Ethmoid sinus	1 (2)	25 (54)	20 (44)	46 (21.1)
Nasal cavity	25 (38)	29 (44)	12 (18)	66 (30.3)
Sinus NOS	1 (25)	0 (0)	3 (75)	4 (1.8)
T stage				
T1	13 (52)	9 (8)	3 (12)	25 (11.5)
T2	11 (21)	34 (67)	6 (12)	51 (23.4)
T3	10 (20)	26 (51)	15 (29)	51 (23.4)
T4	10 (11)	44 (48)	37 (41)	91 (41.7)

NOS: not otherwise specified.

^aData are shown as the number of patients and percentages across lines (two patients who were treated with chemotherapy alone were omitted).

TABLE 5
Actuarial Locoregional Control and Disease Specific Actuarial Survival Rates According to Treatment Modality in Patients with Nasal and Paranasal Sinus Carcinoma

Treatment	No. (%)	Survival (%)			P value
		Two years	Five years	Ten years	
ALRC					
Surgery	44 (20)	74 ± 7	70 ± 7	70 ± 7	—
Surgery and radiotherapy	113 (52)	70 ± 4	63 ± 4	57 ± 8	—
Radiotherapy	61 (28)	47 ± 7	40 ± 7	38 ± 7	0.009
CSAS					
Surgery	44 (20)	84 ± 6	79 ± 6	76 ± 6	—
Surgery and radiotherapy	113 (52)	82 ± 3	66 ± 5	60 ± 5	—
Radiotherapy	61 (28)	59 ± 4	57 ± 8	33 ± 8	0.002

ALRC: actuarial locoregional control; CSAS: carcinoma specific actuarial survival.

tients with invasion of the frontal sinus ($P = 0.05$), sphenoid sinus ($P = 0.003$), cribriform plate ($P = 0.001$), dura ($P < 0.001$), and brain ($P < 0.001$) had an unfavorable prognosis. Contact with the cribriform plate ($P = 0.2$) and orbital extension ($P = 0.6$) were not significant. For patients with disease of the nasal cavity, only invasion of the floor of the nose ($P = 0.04$) and contralateral extension were significant ($P = 0.008$).

Type of Surgery and Local Control

There was no statistical association between the type of surgery (inferior, middle, or total maxillectomy; craniofacial resection; or pterygoid fossa resection)

and local control. The role of enucleation when there was orbital invasion was significant: The ALRC rates were $79\% \pm 9\%$ for patients with enucleation and $14\% \pm 13\%$ for patients without enucleation ($P = 0.03$). Another surgical parameter that reached significance was the positivity of surgical margins: The 2-year and 5-year ALRC rates were $59\% \pm 9\%$ and $45\% \pm 9\%$, respectively, with positive margins, and $70\% \pm 7\%$ and $65\% \pm 7\%$, respectively, with negative margins ($P = 0.05$).

Multivariate Analysis

The variables that reached statistical significance in a multivariate analysis were histology (relative risk,

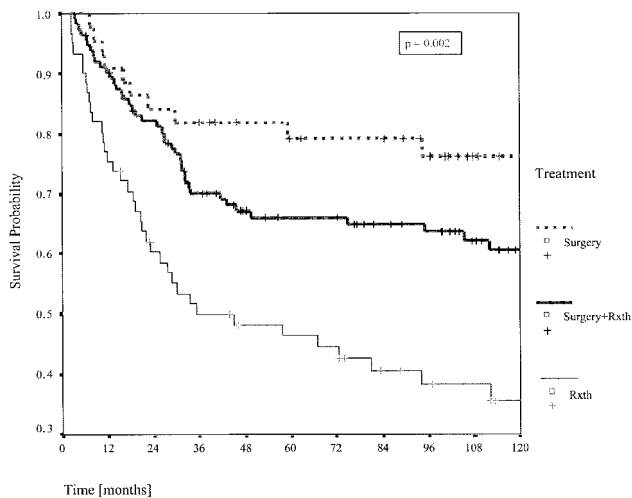


FIGURE 5. Disease specific survival probability according to treatment modality in 218 patients with nasal and paranasal sinus carcinoma. Rxth: radiotherapy.

2.18), local extension to the pterygoid fossa (relative risk, 2.24), and local extension to the dura (relative risk, 3.38). The other variables studied, including T classification, lymph node status, primary tumor site, and treatment type, did not reach statistical significance in multivariate analysis.

Systematic Review

From 1960 to 1998, 154 articles were identified according to the selection criteria. The total number of patients with treatment results in these publications was 16,396. There were 25 articles from the 1960s,^{17-19,60-81} 30 articles from the 1970s,^{16,53,55,82-108} 53 articles from the 1980s,^{5,7,48,54,109-157} and 46 articles from the 1990s.^{11,27,35,40,50,56,58,158-195} Another 137 articles were reviewed but were excluded because they did not fit the inclusion criteria.

The overall survival rate of these patients was 41%. When the global survival data are classified according to the decade of treatment (Table 7), the results show survival rates of 28% \pm 13% in the 1960s, 36% \pm 13% in the 1970s, 43% \pm 15% in the 1980s, and 51% \pm 14% in the 1990s.

The distribution by histology was squamous cell carcinoma in 58% of patients, adenocarcinoma in 16% of patients, and glandular carcinoma and undifferentiated carcinoma in 13% of patients each. The survival rates for patients with squamous cell carcinoma were 25%, 34%, 45%, and 50% in articles from the 1960s, 1970s, 1980s, and 1990s, respectively ($P < 0.001$). Similar improvements in survival were found for patients with glandular carcinoma, whereas data for patients with adenocarcinoma showed little change (Table 7).

The results for patients with undifferentiated carcinoma tended to follow an opposite trend, with worsening results in the 1990s (Fig. 6, top).

The distribution by disease site was the maxillary sinus in 55% patients, the nasal cavity in 23% of patients, the ethmoid sinus in 20% of patients, the sphenoid sinus in 1% of patients, and the frontal sinus in 1% of patients. The survival data per decade showed a progressive improvement in results from the 1960s to the 1990s for patients with maxillary and ethmoid sinus primaries, whereas the results for patients with carcinoma of the nasal cavity appeared to remain stable at around 60% (Table 7; Fig. 6, middle).

The distribution by T classification for patients with carcinoma of the maxillary sinus was 4% T1 tumors, 15% T2 tumors, 40% T3 tumors, and 41% T4 tumors. No significant trend, such as an increase in frequency of lower T classifications across decades, was found (data not shown). Although progressive improvements in the results were seen in most T stages, none reached statistical significance. On average, 12% of patients presented with positive lymph node status.

The treatment modalities used were combined surgery and radiation in 45% of patients, radiation alone in 35% of patients, surgery alone in 15% of patients, and various combinations including chemotherapy in 5% of patients. Again, a progressive improvement was found with all four treatment modalities from the 1960s to the 1990s (Table 7; Fig. 6, bottom), with cure rates during the 1990s of 70% for patients who underwent surgery alone, 56% for patients who underwent combined treatment with surgery and radiation, 33% for patients who underwent radiotherapy alone, and 42% for patients who underwent chemotherapy. The chemotherapy data rarely were based on chemotherapy as the sole treatment but, rather, were based on all treatment modalities that included chemotherapy at some point during the treatment protocol. Therefore, these success rates should not be attributed directly to chemotherapy per se.

DISCUSSION

The presence of large air spaces within the paranasal sinus probably allows the asymptomatic expansion of sinus carcinoma. Early symptoms differ little from common nasal complaints,^{6,117,154} and their temporary regression by antibiotics falsely reassures both the patient and the physician. When more alarming symptoms, such as ocular complaints, cranial nerve deficits, or cheek mass, are apparent, the outcome tends to be less favorable.¹¹¹ It is unclear whether the recent, widespread use of nasal endoscopy and radio-

TABLE 6
Outcome According to First Oncologic Event^a

Outcome	Regional recurrence (%)		Absence of regional recurrence (%)		Total (%)
	Distant metastasis	Absence of distant metastasis	Distant metastasis	Absence of distant metastasis	
Local recurrence	2 (1)	4 (2)	7 (3)	73 (35)	86 (41)
Absence of local recurrence	0 (0)	8 (4)	9 (4)	106 (51)	123 (59)
Total	2 (1)	12 (6)	16 (7)	179 (86)	209

^a Eleven patients with insufficient data were excluded.**TABLE 7**
Meta-Analysis Data: Cross Tabulation of Histology, Site, T-Classification, and Treatment Modality by Decade of Publication

Characteristic	Decade (%)				P value
	1960s	1970s	1980s	1990s	
No. of studies	25	30	53	46	—
No. of patients	3137	3877	5966	3416	—
Histology					
Squamous cell carcinoma	25 ± 13	34 ± 15	45 ± 19	50 ± 19	< 0.001
Glandular carcinoma	42 ± 33 ^a	30 ± 17 ^a	45 ± 21	60 ± 24	0.09
Adenocarcinoma	46 ± 33	48 ± 28	49 ± 29	50 ± 14	0.83
Undifferentiated carcinoma	23 ± 17	42 ± 21	30 ± 17	28 ± 21	0.41
Site					
Maxillary sinus	26 ± 13	31 ± 8	39 ± 14	45 ± 11	0.02
Ethmoid sinus	27 ± 13	37 ± 13	56 ± 24	51 ± 15	0.002
Nasal cavity	63 ± 23	54 ± 25	59 ± 12	66 ± 15	0.71
T classification					
T1	28 ^a	83 ± 29	87 ± 23	90 ± 19	0.25
T2	22 ^a	53 ± 22	62 ± 27	70 ± 30	0.28
T3	10 ^a	28 ± 14	44 ± 17	44 ± 29	0.13
T4	0 ^a	18 ± 11	19 ± 10	28 ± 18	0.31
Treatment					
Surgery	36 ± 25	54 ± 15	57 ± 26	70 ± 20	0.034
Surgery and radiotherapy	33 ± 18	42 ± 15	54 ± 15	56 ± 13	< 0.001
Radiotherapy	21 ± 13	19 ± 17	28 ± 20	33 ± 18	0.048
Chemotherapy ^b	0 ^a	21 ± 18	34 ± 24	42 ± 18	0.10
Overall	28 ± 13	36 ± 13	44 ± 15	51 ± 14	< 0.001

^a Included fewer than five studies.^b The chemotherapy data include patients who received chemotherapy as part of their treatment, usually combined with other modalities.

logic studies will result in earlier diagnoses of nasal and paranasal sinus carcinoma.

Overall Results

In our series, the overall survival rate was 40%, and intercurrent deaths occurred in 14.5% of patients, for a disease specific survival rate of 54.5%. The 5-year CSAS rate was 63%. The results in terms of locoregional control paralleled the survival data, with a 5-year ALRC rate of 57%. The close relation between

survival and local control underscores the fact that the prognosis for patients with nasal and paranasal sinus carcinoma is related directly to local control of the disease.^{4,5,103,117,154,157,174,186,196}

In the literature, global results, most often expressed in terms of crude survival, vary between 10%^{60,61,63,70,77,80,82,152} and 75%,^{40,106,109,132,135,160,161,165,176} with better results in carefully selected patients, in patients with primary tumors of the nasal cavity, and in more recently published articles. The average over-

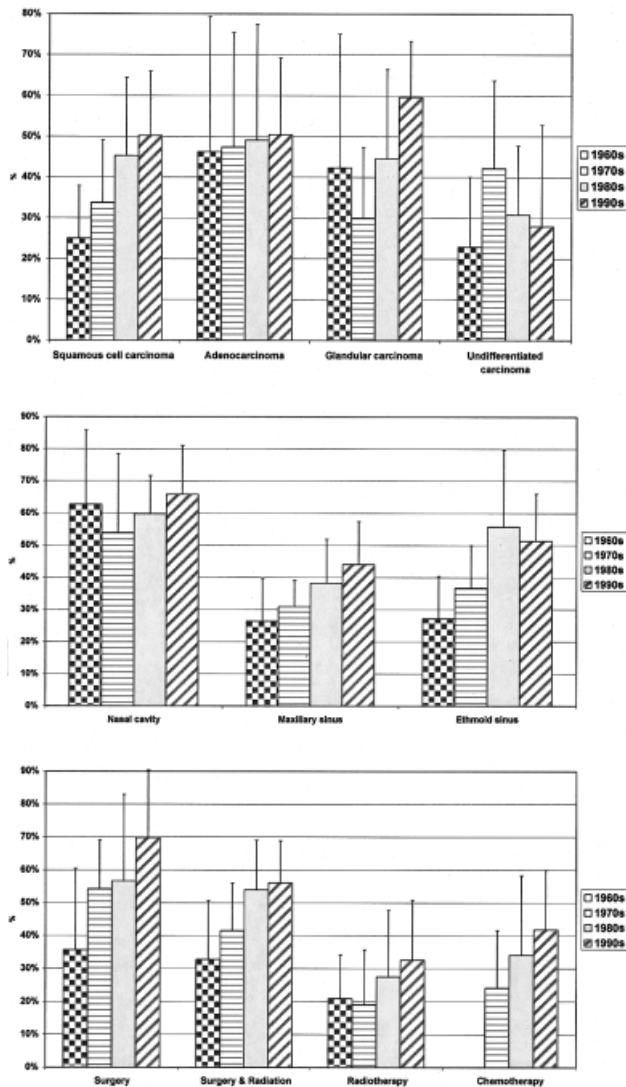


FIGURE 6. Bar plots from the meta-analysis data grouped according to four successive decades of publication: 1960s, 1970s, 1980s, and 1990s. The top plot shows survival results according to histology, the middle plot shows survival results according to tumor location, and the bottom plot shows survival results according to the treatment used.

all survival rate from the systematic review analysis was 41%, and the overall survival rate for the 1990s was 51%.

Histology

Tumor histology was related statistically to outcome in both the univariate and multivariate statistical analyses. Our 5-year CSAS rates were 78% for patients with adenocarcinoma and glandular carcinoma, 60% for patients with squamous cell carcinoma, and 40% for patients with undifferentiated carcinoma. The survival curves according to histology exhibited different pat-

terns: patients with squamous cell carcinoma failed essentially in the first 2–3 years, whereas patients with adenocarcinoma and glandular carcinoma experienced disease recurrences at a low but steady rate for up to 10 years after treatment. Patients with undifferentiated carcinoma exhibited an intermediate survival curve with early as well as late failures.

The current results are somewhat better, even compared with the meta-analysis results tabulated for the 1990s. Possible explanations include our use of disease specific actuarial data and the focus of recent articles on specific surgical procedures instead of describing the results from a histologic or tumor location point of view. Several articles on patients who underwent craniofacial resection reported results as good as ours, but the results could not be included in the meta-analysis either because of large numbers of tumors with noncarcinoma histologies or because of a short follow-up.^{8,9,46,197–199} Nevertheless, several reports related outcomes better than ours for patients with squamous cell carcinoma,^{48,56,106,100,110,117,132,137,147,160,168,176} for patients with glandular carcinoma,^{160,168,184} and for patients with adenocarcinoma.^{136,146}

The systematic review revealed a steady improvement in treatment results for patients with squamous cell carcinoma and glandular carcinoma (Fig. 6, top). The poor results for patients with undifferentiated carcinoma may be explained by the description of nasal undifferentiated sinonasal carcinoma in 1986^{200,201} as a separate entity with aggressive oncologic behavior. Possibly, a more precise pathologic diagnosis has resulted in the exclusion of patients with less aggressive carcinoma from this group.

Location

In our series and in the literature, half of all patients with nasal and paranasal carcinoma had disease that arose from the maxillary sinus, with the remaining half divided equally between nasal cavity and ethmoid sinus primary tumors. Patients with frontal and sphenoid sinus carcinoma were grouped with patients with carcinoma of the ethmoid sinus and were staged as T4, a reasonable approximation in view of the rarity, location, and oncologic behavior of these tumors.

Our 5-year CSAS rate was 77% for patients with nasal carcinoma, 62% for patients with maxillary primary tumors, and 48% for patients with carcinoma of the ethmoid sinus. Better results for patients with nasal carcinoma were noted previously by Frazell and Lewis in 1963¹⁷ and were confirmed in recent reports.^{81,106,133,156,162,165} The systematic review data are comparable to ours, with CSAS rates in the 1990s of 45% for patients with carcinoma of the maxillary sinus, 51% for patients with carcinoma of the ethmoid

sinus, and 66% for patients with nasal carcinoma. There was a steady improvement in the treatment results for patients with maxillary and ethmoid primary tumors, while the results for patients with nasal carcinoma have stagnated, for unclear reasons, around 60% since the 1960s.

T Classification

The diagnosis of nasal and paranasal carcinoma occurred at an advanced stage in our patients, and this distinction also was seen in other publications,^{5,11,103,111,117,154,176} with 70–80% of patients diagnosed with T3 or T4 tumors. It has been reported that improvements in treatment results for patients with malignant disease represent spurious effects of diagnosis at an early stage²⁰²; however, no such trend for lower T classifications could be found in the systemic review.

A clear correlation between T stage and survival was found in univariate analysis for all locations. This was noted in previous articles on patients with primary tumors of the maxillary sinus.^{5,90,92,95,104,117,126,137,144,154,155,157,162,173} Our 5-year CSAS rates were 91%, 64%, 70%, and 50% for patients with T1, T2, T3, and T4 tumors, respectively. These results are close to the meta-analysis data from the 1990s for patients with T1 tumors (94%) and T2 tumors (55%), but they are much better compared with the results for patients with T3 tumors (50%) and T4 tumors (27%). Possibly, the use of more extensive surgical resections in our series, the presence of numerous exclusive radiotherapy reports in the literature with less favorable outcomes for patients with advanced-stage disease, and the bias of recent surgical publications discussed above may provide explanations for these differences.

Articles that employed a staging system for patients with nasal and ethmoid carcinoma were sparse, and the classification systems used varied^{14,29,30,77,100,109,151,165,171,188,196,203} and sometimes were arbitrary^{57,74,107,108,110,130,156,162,204–206} Only one previous study used a similar classification system in 54 patients with nasal and paranasal carcinoma¹⁸³: The 5-year survival rates found were 100% for patients with T1 tumors, 87.5% for patients with T2 tumors, 92.3% for patients with T3 tumors, 28% for patients with T4 tumors.

It is difficult to compare our data in terms of disease stage for these locations until a universal staging system is adopted. For this study, we reluctantly abandoned the staging system that we proposed several years ago for patients with esthesioneuroblastoma^{4,207} in favor of the UICC classification system in the search for such a consensus. However, the proposed UICC system for classifying patients with tu-

mors of the ethmoid and nasal cavity has numerous shortcomings and may explain the paucity of differences between the results for patients with T2 and T3 tumors.

Treatment Modality

Our data show a 5-year CSAS rate of 57% for patients who underwent radiation alone, 66% for patients who underwent combined radiation and surgery, and 79% for patients who underwent surgery alone. The difference was highly significant in the log-rank analysis, as suggested in previous reports.^{17,66,76,95,96,104,111,134,135,139,154,167,169,180}

The meta-analysis confirmed that surgery (70%) and combined surgery and radiation (56%) offer better local control and cure rates than radiotherapy alone (33%). Most series, including ours, are biased in patient selection, and no randomized study has been published. In general, patients with favorable lesions are found mainly in the surgery alone groups, whereas patients with large lesions and those who are treated for palliation are in the exclusive radiation or chemoradiation groups. Nevertheless, except for a few articles,^{76,77,113,160,184} the results of radiation alone are poorer than treatments that include surgery. Furthermore, radical radiotherapy protocols have resulted in 20%¹¹ to 30%⁵⁶ unilateral blindness and 6%¹¹ to 10%⁵⁶ bilateral blindness. Despite the inherent patient selection bias of retrospective studies, the available data suggest that surgery should be included in the treatment strategy for patients with nasal and paranasal carcinoma who are treated with a curative intent.

The sequence of surgery and radiotherapy in the management of these patients has remained open to debate since the work of Jesse,⁷¹ who showed no clear difference. Although most centers prefer primary surgery, some continue to choose primary radiotherapy.^{120,146,154,162,167,184,188} Because a high incidence of residual disease is found after primary radiation,^{74,137,147} the main goal of primary radiation often is to shrink the tumor so that the surgical resection is less extensive and vital structures, such as the eye, can be spared.^{154,184,185} The use of hyperfractionation^{11,142} or neutron beam irradiation¹⁴² does not seem to modify the cure rates drastically. Although the results of a few recent articles that included chemotherapy in the treatment protocol are encouraging, with 5-year survival rates > 50%,^{34,40,136,137,173} it remains unclear whether the addition of chemotherapy to other aggressive treatment regimens provides a clear advantage in local control or survival.

Local Extension

The air-filled sinus cavities offer little resistance to tumor growth. Sinus carcinoma probably expands by filling the cavity first, before eroding the adjacent bony walls in a centrifugal pattern. Fibroelastic connective tissue present in periosteum, perichondrium, and dura is considered the most efficient barrier to disease expansion.⁶ The pathologic studies addressing the natural barriers to sinonasal carcinoma invasion are lacking.

In the current series, the patients with extensions toward the anterior base of skull and toward the pterygomaxillary fossa had a worse prognosis in both univariate and multivariate analyses. Keeping in mind the importance of local control, further advancement in treatment should address these structures specifically. For patients who undergo surgery, en bloc resection, including surrounding noninvaded osseous walls, is favored. In patients with high nasal and ethmoid carcinoma, craniofacial resection by combined cranial and transfacial approaches has become a routine procedure^{4,22,48,174,176,178} and probably is responsible for the improved results in this and other series.^{154,176} Similarly, patients with invasion beyond the maxillary walls undergo mandibulectomy for the lateral wall and infratemporal fossa²³ and sphenoid wing resection¹⁷⁶ for the posterior wall. The evolution from the piecemeal surgical procedures performed in the 1960s can be seen in Table 7: Note the improvements in the 5-year survival rate from 36% in the 1960s to 70% in the 1990s, notwithstanding patient selection.

Orbital invasion is always dramatic and, despite modern radiologic techniques, often is diagnosed correctly only during exploration.²⁰⁸ Since the report by Larsson et al.,²⁰⁹ several authors have advocated an eye-sparing approach.^{45,174,210–212} Although it seems reasonable that an intact orbit should mandate eye preservation, the available data are inconclusive at best,¹⁹¹ and preservation does not necessarily result in an intact functional eye.⁴⁵ Our data show that, in patients with orbital invasion, the local control rate is 79% with enucleation and 14% without enucleation. Despite the biases inherent to a retrospective study, it probably is unwise to conclude that the orbit can be spared in all patients.²¹¹

Metastasis and Recurrences

Fortunately, neck lymph metastases remain infrequent either at the time of presentation or after treatment. In our data, 2.3% of patients presented with a neck metastasis, and 7% of patients developed a neck metastasis. In the meta-analysis, the corresponding rates were 12% and 13%. Neck lymph node recurrence

alone was present in 4% of our patients and in 5% of patients in the meta-analysis data. In some series that were weighted heavily toward patients with advanced-stage maxillary squamous cell carcinoma,^{5,117,137,148,174,213} the rate of neck metastasis at the time of presentation was \approx 20–25%, and prophylactic treatment of the neck should have been considered.^{5,56,174,213} Several studies^{137,194,214} have indicated a higher incidence of neck recurrence with involvement of the alveolus and cheek.

The results of treatment for patients with metastatic neck disease were disappointing. However, patients with primary neck metastases had a 20% 5-year survival rate in the current series and a 32% 5-year survival rate in the systematic review. For patients with post-treatment neck metastases, the 5-year survival rates were 21% in the current series and 25% in the meta-analysis. Our success rate in the treatment of patients with local recurrences was 13% and was comparable to the 16% rate found in the meta-analysis.

Shortcomings of the Study

Although this patient series was relatively large, it suffered from the usual shortcomings of any retrospective study: mainly, a retrospective staging in some patients and nonrandomized treatment selection. The systematic review theoretically may strengthen the conclusions, and this represents the rationale for undertaking it. Notwithstanding criticisms of meta-analysis in general and specific and pertinent criticisms of meta-analysis of observational studies, we tend to think that our systemic review may be the only means of gaining a global perspective.^{32,33} Because of the heterogeneity of the studies and the lack of possible quality control, the results of the systematic review should be taken as a general indication of our current achievements in the treatment of patients with nasal and paranasal carcinoma.

REFERENCES

1. Muir CS, Nectoux J. Descriptive epidemiology of malignant neoplasms of nose, nasal cavities, middle ear and accessory sinuses. *Clin Otolaryngol* 1980;5:195–211.
2. Ayiomamitis A, Parker L, Havas T. The epidemiology of malignant neoplasms of the nasal cavities, the paranasal sinuses and the middle ear in Canada. *Arch Otorhinolaryngol* 1988;244:367–71.
3. Shanmugaratnam K, Sobin LH. Histological typing of tumours of the upper respiratory tract and ear. Berlin: Springer-Verlag, 1991.
4. Dulguerov P, Calcaterra TC. Esthesioneuroblastoma—the UCLA experience. *Laryngoscope* 1992;102:843–9.
5. Lavertu P, Roberts JK, Kraus DH, Levine HL, Wood BG, Mendendorp SV, et al. Squamous cell carcinoma of the paranasal sinuses: the Cleveland Clinic experience 1977–1986. *Laryngoscope* 1989;99:1130–6.

6. Lyons BM, Donald PJ. Radical surgery for nasal cavity and paranasal sinus tumors. *Otolaryngol Clin North Am* 1991;24:1499–521.
7. Ketcham AS, Van Buren JM. Tumors of the paranasal sinuses: a therapeutic challenge. *Am J Surg* 1985;150:406–13.
8. Catalano PJ, Hecht CS, Biller HF, Lawson W, Post KD, Sachdev V, et al. Craniofacial resection. An analysis of 73 cases. *Arch Otolaryngol Head Neck Surg* 1994;120:1203–8.
9. Richtsmeier WJ, Briggs RJS, Koch WM, Eisele DW, Loury MC, Price JC, et al. Complications and early outcome of anterior craniofacial resection. *Arch Otolaryngol Head Neck Surg* 1992;118:913–7.
10. Donald PJ. Complications in skull base surgery for malignancy. *Laryngoscope* 1999;109:1959–66.
11. Parsons JT, Kimsey FC, Mendenhall WM, Million RR, Cassisi NJ, Stringer SP. Radiation therapy for sinus malignancies. *Otolaryngol Clin North Am* 1995;28:1259–68.
12. Shukovsky LJ, Fletcher GH. Retinal and optic nerve complications in a high dose irradiation technique of ethmoid sinus and nasal cavity. *Radiology* 1972;104:629–34.
13. Takeda A, Shigematsu N, Suzuki S, Fujii M, Kawata T, Kawaguchi O, et al. Late retinal complications of radiation therapy for nasal and paranasal malignancies: relationship between irradiated-dose area and severity. *Int J Radiat Oncol Biol Phys* 1999;44:599–605.
14. Syme J. Excision of upper jaw bones. *Lancet* 1829;2:667–8.
15. Schuknecht HF. The surgical management of carcinoma of the paranasal sinuses. *Laryngoscope* 1951;874–90.
16. Lewis JS, Castro EB. Cancer of the nasal cavity and paranasal sinuses. *J Laryngol Otol* 1972;86:255–86.
17. Frazell EL, Lewis JS. Cancers of the nasal cavity and accessory sinuses. A report of the management of 416 patients. *Cancer* 1963;16:1293–301.
18. Baclesse F, Ennuyer A, Calle R. Les épithéliomas du sinus maxillaire traités par roentgenthérapie transcutanée seule (résultats à cinq ans). *J Radiol Electrol* 1960;41:368–75.
19. Pointon RCS. Neoplasia of the nose and sinuses. *J Laryngol Otol* 1969;83:407–15.
20. Bailar JC, Gornik HL. Cancer undefeated. *N Engl J Med* 1997;336:1569–74.
21. Smith RR, Klopp CT, Williams JM. Surgical treatment of cancer of the frontal sinus and adjacent areas. *Cancer* 1954;7:991–9.
22. Ketcham AS, Wilkins RH, Van Buren JM, Smith RR. A combined intracranial facial approach to the paranasal sinuses. *Am J Surg* 1963;106:698–703.
23. Terz JJ, Alksne JF, Lawrence W. Craniofacial resection for tumors invading the pterygoid fossa. *Am J Surg* 1969;118:732–9.
24. Janecka IP, Nuss DW, Sen CN. Facial translocation approach to the cranial base. *Acta Neurochir* 1991;53(Suppl):193–8.
25. Gademann G, Schlegel W, Debus J, Schad L, Bortfeld T, Hover KH, et al. Fractionated stereotactically guided radiotherapy of head and neck tumors: a report on clinical use of a new system in 195 cases. *Radiat Oncol* 1993;29:205–13.
26. Miralbell R, Crowell C, Suit HD. Potential improvement of three dimension treatment planning and proton therapy in the outcome of maxillary sinus cancer. *Int J Radiat Oncol Biol Phys* 1991;22:305–10.
27. Roa WH, Hazuka MB, Sandler HM, Martel MK, Thornton AF, Turrisi AT, et al. Results of primary and adjuvant CT-based 3-dimensional radiotherapy for malignant tumors of the paranasal sinuses. *Int J Radiat Oncol Biol Phys* 1994;28:857–65.
28. Mosesson RE, Som PM. The radiographic evaluation of sinonasal tumors: an overview. *Otolaryngol Clin North Am* 1995;28:1097–115.
29. Hermanek P, Henson DE, Hutter RVP, Sobin LH. International Union Against Cancer: TNM supplement 1993. Berlin: Springer, 1993.
30. Sobin LH, Wittekind C. International Union Against Cancer: TNM classification of malignant tumors. Berlin: Springer, 1997.
31. Egger M, Smith GD. Meta-analysis. Potentials and promise. *BMJ* 1997;315:1371–4.
32. Egger M, Schneider M, Davey Smith G. Spurious precision? Meta-analysis of observational studies. *BMJ* 1998;316:140–4.
33. Stroup DF, Berlin JA, Morton SC, Olkin I, Williamson GD, Rennie D, et al. Meta-analysis of observational studies in epidemiology: a proposal for reporting. Meta-analysis of Observational Studies in Epidemiology (MOOSE) group. *JAMA* 2000;283:2008–12.
34. Roux FX, Brasnu D, Menard M, et al. Adenocarcinoma of the ethmoid sinuses. Results of a new protocol based on inductive chemotherapy combined with surgery. Four years experience. *Acta Neurochir (Wien)* 1989;98:129–34.
35. Roux FX, Brasnu D, Menard M, et al. Les abords combinés des tumeurs malignes de l'ethmoïde et autres sinus paranasaux. Principes et résultats. *Ann Otolaryngol Chir Cervicofac* 1991;108:292–7.
36. Roux FX, Brasnu D, Devaux B, Chabardes E, Schwaab G, Laccourreye O, et al. Ethmoid sinus carcinomas: results and prognosis after neoadjuvant chemotherapy and combined surgery—a 10-year experience. *Surg Neurol* 1994;42:98–104.
37. Roux FX, Devaux B, Nataf F, Pages JC, Laccourreye O, Menard M, et al. Malignant tumors of the ethmoid region. Neurosurgical techniques. *Neurochirurgie* 1997;43:92–9.
38. Roux FX, Pages JC, Nataf F, Devaux B, Laccourreye O, Menard M, et al. Les tumeurs malignes ethmoïdo-sphénoïdales. 130 cas. Etude retrospective. *Neurochirurgie* 1997;43:100–10.
39. Brasnu D, Roux FX, Fabre A, Menard M, Manolopoulos L, Chodkiewicz JP, et al. La voie d'abord combinée ORL et Neurochirurgicale dans les adénocarcinomes de l'ethmoïde. *Ann Otolaryngol Chir Cervicofac* 1987;104:347–51.
40. Brasnu D, Laccourreye O, Bassot V, Laccourreye L, Naudo P, Roux FX. Cisplatin-based neoadjuvant chemotherapy and combined resection for ethmoid sinus adenocarcinoma reaching and/or invading the skull base. *Arch Otolaryngol Head Neck Surg* 1996;122:765–8.
41. Brasnu D, Laccourreye O, Menard M, Devaux B, Roux FX. Approches transfaciales des cancers de l'ethmoïde. *Neurochirurgie* 1997;43:88–91.
42. Schwaab G, Marandas P. Les problèmes du traitement chirurgical des tumeurs malignes de l'ethmoïde par abord mixte endocranien et facial. *Ann Otolaryngol Chir Cervicofac* 1983;100:159–61.
43. Schwaab G, Julieron M, Janot F. Epidémiologie des cancers de la fosse nasale et sinus paranasaux. *Neurochirurgie* 1997;43:61–3.
44. George B, Salvan D, Luboinski B, Boissonnet H, Lot G. Tumeurs malignes de l'ethmoïde. Série homogène de 41 cas opérés par voie mixte. *Neurochirurgie* 1997;43:121–4.
45. Andersen PE, Kraus DH, Arbit E, Shah JP. Management of the orbit during anterior fossa craniofacial resection. *Arch Otolaryngol Head Neck Surg* 1996;122:1305–7.

46. Bilsky MH, Kraus DH, Strong EW, Harrison LB, Gutin PH, Shah JP. Extended anterior craniofacial resection for intracranial extension of malignant tumors. *Am J Surg* 1997;174:565-8.
47. Harrison LB, Pfister DG, Kraus D, et al. Management of unresectable malignant tumors at the skull base using concomitant chemotherapy and radiotherapy with accelerated fractionation. *Skull Base Surg* 1994;4:127-31.
48. Shah JP, Sundaresan N, Galicich J, Strong EW. Craniofacial resections for tumors involving the base of the skull. *Am J Surg* 1987;154:352-8.
49. Shah JP, Kraus DH, Arbit E, Galicich JH, Strong EW. Craniofacial resection for tumors involving the anterior skull base. *Otolaryngol Head Neck Surg* 1992;106:387-93.
50. Shah JP, Kraus DH, Bilsky MH, Gutin PH, Harrison LH, Strong EW. Craniofacial resection for malignant tumors involving the anterior skull base. *Arch Otolaryngol Head Neck Surg* 1997;123:1312-7.
51. Blacklock JB, Weber RS, Lee YY, Goepfert H. Transcranial resection of tumors of the paranasal sinuses and nasal cavity. *J Neurosurg* 1989;71:10-5.
52. McCutcheon IE, Blacklock JB, Weber RS, DeMonte F, Moser RP, Byers M, et al. Anterior transcranial (craniofacial) resection of tumors of the paranasal sinuses: surgical technique and results. *Neurosurgery* 1996;38:471-80.
53. Goepfert H, Jesse RH, Lindberg RD. Arterial infusion and radiation therapy in the treatment of advanced cancer of the nasal cavity and paranasal sinuses. *Am J Surg* 1973;126:464-8.
54. Goepfert H, Luna MA, Lindberg RD, White AK. Malignant salivary gland tumors of the paranasal sinuses and nasal cavity. *Arch Otolaryngol* 1983;109:662-8.
55. Jesse RH, Goepfert H, Linberg RD. Squamous cell carcinoma of maxillary and ethmoid sinuses. *Proc Natl Cancer Conf* 1973;7:193-7.
56. Jiang GL, Ang KK, Peters LJ, Wendt CD, Oswald MJ, Goepfert H. Maxillary sinus carcinoma: natural history and results of postoperative radiotherapy. *Radiother Oncol* 1991;21:193-200.
57. Lee YY, Dimery IW, Van Tassel P, De Pena C, Blacklock JB, Goepfert H. Superselective intra-arterial chemotherapy of advanced paranasal sinus tumors. *Arch Otolaryngol Head Neck Surg* 1989;115:503-11.
58. Salvan D, Julieron M, Marandas P, Janot F, Leridant AM, Domenge C, et al. Combined transfacial and neurosurgical approach to malignant tumours of the ethmoid sinus. *J Laryngol Otol* 1998;112:446-50.
59. Clarke M, Oxman AD. Cochrane reviewers's handbook 4.0. Review manager (RevMan) computer program. Oxford, England: The Cochrane Collaboration, 1999.
60. Chaudry AP, Gorlin RJ, Moser DG. Carcinoma of the antrum. A clinical and histopathologic study. *Oral Surg Oral Med Oral Pathol* 1960;13:269-81.
61. Cocchi VU. Die Strahlentherapie des malignen Tumoren der inneren Nase und der Nasennebenhölen. *Oncologia* 1960;13:370-80.
62. Fitz-Hugh G, Gorman J. Cancer of the nasal accessory sinuses. *South Med J* 1960;53:155-61.
63. Markowitz AM. Malignant tumors of the upper jaw. *Surgery* 1960;47:443-52.
64. Osborn DA, Winston P. Carcinoma of the paranasal sinuses. *J Laryngol Otol* 1961;75:387-405.
65. Rossi G, Demichelis G, Cherubini E. Primary malignant tumours of the maxillary sinus. *Acta Otolaryngol* 1962;S181:1-43.
66. Tabah EJ. Cancer of the paranasal sinuses. A study of the results of various methods of treatment in fifty-four patients. *Am J Surg* 1962;104:741-5.
67. Vaheri E, Setala H. Malignant tumors of paranasal sinuses. *Acta Otolaryngol* 1962;54:561-72.
68. Deeley TJ, Morrison R. Treatment of malignant disease of the nasal sinuses by supervoltage radiotherapy. *J Laryngol Otol* 1963;77:43-9.
69. Salem LE, Zaharia M, Travezan R. Carcinoma of the paranasal sinuses. *Am J Surg* 1963;106:826-30.
70. Spratt JS, Mercado R. Therapy and staging in advanced cancer of the maxillary antrum. *Am J Surg* 1965;110:502-9.
71. Jesse RH. Preoperative versus postoperative radiation in the treatment of squamous carcinoma of the paranasal sinuses. *Am J Surg* 1965;110:552-6.
72. Macbeth R. Malignant disease of the paranasal sinuses. *J Laryngol Otol* 1965;79:592-612.
73. Baker R, Cherry J, Lott S, Bischofberger WB. Carcinoma of the maxillary sinus. *Arch Otolaryngol* 1966;84:201-4.
74. Ireland PE, Bryce DP. Carcinoma of the accessory nasal sinuses. *Ann Otol Rhinol Laryngol* 1966;75:698-713.
75. Holsti LR, Rinne R. Treatment of malignant tumours of paranasal sinuses. *Acta Radiol* 1967;6:337-50.
76. Boone MLM, Harle TS, Higholt HW, Fletcher GH. Malignant disease of the paranasal sinuses and nasal cavity. *Am J Roentgenol* 1968;102:627-36.
77. Badib AO, Kurohara SS, Webster JH, Shedd DP. Treatment of cancer of the nasal cavity. *Am J Roentgenol Radium Ther Nucl Med* 1969;106:824-30.
78. Badib AO, Kurohara SS, Webster JH, Shedd DP. Treatment of cancer of the paranasal sinuses. *Cancer* 1969;23:533-7.
79. Leroux-Robert J. Epithéliomas du massif ethmoïdo-maxillaire. Etude statistique de 215 cas opérés plus de 5 ans. *Ann Otolaryngol (Paris)* 1969;86:5-12.
80. Marchetta FC, Sako K, Mattick WL, Stinziano GD. Squamous cell carcinoma of the maxillary antrum. *Am J Surg* 1969;118:805-7.
81. Rafla S. Mucous gland tumors of paranasal sinuses. *Cancer* 1969;24:683-91.
82. Bennett M. Paranasal sinus malignancies (a review of sixty cases). *Laryngoscope* 1970;80:933-43.
83. Gallagher TM, Boles R. Symposium: treatment of malignancies of paranasal sinuses. I. Carcinoma of the maxillary antrum. *Laryngoscope* 1970;80:924-32.
84. Hamberger CA, Martensson G. Carcinoma of the paranasal sinuses, combined approach. *Radiat Ther Oncol* 1970;5:130-46.
85. Lederman M. Tumors of the upper jaw: natural history and treatment. *J Laryngol Otol* 1970;84:369-401.
86. Bataini JP, Ennuyer A. Advanced carcinoma of the maxillary antrum treated by cobalt teletherapy and electron beam irradiation. *Br J Radiol* 1971;44:590-8.
87. Tabb HG, Barranco SJ. Cancer of the maxillary sinus. *Laryngoscope* 1971;81:818-27.
88. Sanchez-Casis G, Devine KD, Weiland LH. Nasal adenocarcinoma that closely simulate colonic carcinomas. *Cancer* 1971;28:714-20.
89. Birkhead BM, Scott RM. integrated therapy of cancer of the maxillary antrum. *Cancer* 1972;30:665-7.
90. De La Cruz A, Chandler JR. Malignant neoplasms of the paranasal sinuses. *South Med J* 1972;65:727-31.

91. Kurohara SS, Webster JH, Ellis. Role of radiation therapy and surgery in the management of localized epidermoid carcinoma of the maxillary antrum. *AJR* 1972;114:35–43.
92. Schechter GL, Ogura JH. Maxillary sinus malignancy. *Laryngoscope* 1972;82:796–807.
93. Ketcham AS, Chretien PB, Van Buren JM, Hoze RC, Beazley RM, Herdt JR. The ethmoid sinuses: a re-evaluation of surgical resection. *Am J Surg* 1973;126:469–76.
94. Matsumura Y, Soda T, Motomura K. Combined treatment for carcinoma of the paranasal sinuses with irradiation and bleomycin. *Ear Nose Throat J* 1973;4:4–11.
95. Rybak LP, Lehman RH. Nasal cavity and paranasal sinus malignancies: review of 41 cases. *Wisconsin Med J* 1973;72:257–60.
96. Adams G, Duvall AJ, Smith D, Pollak K. Malignant tumors of the paranasal sinuses. *Minn Med* 1974;57:562–8.
97. Som ML. Surgical management of carcinoma of the maxilla. *Arch Otolaryngol* 1974;99:270–3.
98. Gamez-Araujo JJ, Ayala AG, Guillaumondegui O. Mucous adenocarcinoma of nose and paranasal sinuses. *Cancer* 1975;36:1100–5.
99. Barley VL, Paine CH. Carcinoma of the maxillary antrum. *Proc R Soc Med* 1976;69:697–700.
100. Bosch A, Vallecillo L, Frias Z. Cancer of the nasal cavity. *Cancer* 1976;37:1458–63.
101. Helman P, Sealy R. The treatment of locally advanced cancer of the head and neck, with special reference to upper jaw tumours. *J Laryngol Otol* 1976;90:49–58.
102. Saunders SH, Ruff T. Adenocarcinoma of the para-nasal sinuses. *J Laryngol Otol* 1976;90:157–66.
103. Cheng VST, Wang CC. Carcinomas of the paranasal sinuses. A study of sixty-six cases. *Cancer* 1977;40:3038–41.
104. Jackson RT, Fitz-Hugh GS, Constable WC. Malignant neoplasms of the nasal cavity and paranasal sinuses: a retrospective study. *Laryngoscope* 1977;87:726–36.
105. Bridger MWM, Beale FA, Bryce DP. Carcinoma of the paranasal sinuses—a review of 158 cases. *J Otolaryngol* 1978;7:379–88.
106. Ellingwood KE, Million RR. Cancer of the nasal cavity and ethmoid/sphenoid sinuses. *Cancer* 1979;43:1517–26.
107. Müller RP, Castrup W, Baumeister S, Burkhardtmaier G. Zur Therapie der Malignome der Nasenhaupt- und nebenhölen. *Stralenterapie* 1979;155:149–53.
108. Young JR. Malignant tumors of the nasal septum. *J Laryngol Otol* 1979;93:817–32.
109. Chung CT, Rabuzzi DD, Sagerman RH, King GA, Gacek RR. Radiotherapy for carcinoma of the nasal cavity. *Arch Otolaryngol* 1980;106:763–6.
110. Konno A, Togawa K, Inoue S. Analysis of the results of our combined therapy for maxillary cancer. *Acta Otolaryngol* 1980;372(Suppl):1–15.
111. Weymuller EA, Reardon EJ, Nash D. A comparison of treatment modalities in carcinoma of the maxillary antrum. *Arch Otorhinolaryngol* 1980;106:625–9.
112. Ahmad R, Cordoba RB, Fayos JV. Squamous cell carcinoma of the maxillary sinus. *Arch Otorhinolaryngol* 1981;107:48–51.
113. Amendola BE, Eisert D, Harza TA, King ER. Carcinoma of the maxillary antrum. *Int J Radiat Oncol Biol Phys* 1981;7:743–6.
114. Lee F, Ogura JH. Maxillary sinus carcinoma. *Laryngoscope* 1981;91:133–9.
115. Robin PE, Powell DJ. Treatment of carcinoma of the nasal cavity and paranasal sinuses. *Clin Otolaryngol* 1981;6:401–14.
116. Beatty CW, Pearson BW, Kern EB. Carcinoma of the nasal septum: experience with 85 cases. *Otolaryngol Head Neck Surg* 1982;90:90–4.
117. Bush SE, Bagshaw MA. Carcinoma of the paranasal sinuses. *Cancer* 1982;50:154–8.
118. Frich JC. Treatment of advanced squamous cell carcinoma of the maxillary sinus by irradiation. *Int J Radiat Oncol Biol Phys* 1982;8:1453–9.
119. Heffner DK, Hyams VJ, Hauck KW, Lingeman C. Low-grade adenocarcinoma of the nasal cavity and paranasal sinuses. *Cancer* 1982;50:312–22.
120. Hu YH, Tu GY, Qi YQ, Xu GS, Wu XL, Cai WM, et al. Comparison of pre- and postoperative radiation in the combined treatment of carcinoma of the maxillary sinus. *Int J Radiat Oncol Biol Phys* 1982;8:1045–9.
121. Beale FA, Garrett PG. Cancer of the paranasal sinuses with particular reference to maxillary sinus cancer. *J Otolaryngol* 1983;12:377–82.
122. Gullane P, Conley J. Carcinoma of the maxillary sinus. *J Otolaryngol* 1983;12:141–5.
123. Marandas P, Lecointre F, Micheau C, Wibault P, Eschwege F, Richard J, et al. Cancers des cavités naso-sinusiennes—intérêt de la chimiothérapie intra-artérielle. *J Otolaryngol* 1983;12:45–9.
124. Lund VJ. Malignant tumors of the nasal cavity and paranasal sinuses. *ORL J Otorhinolaryngol Relat Spec* 1983;45:1–12.
125. Majumdar B, Kent S. Malignant neoplasms of the nose and paranasal sinuses. A survey of cases treated in a regional centre. *Clin Otolaryngol* 1983;8:97–102.
126. St Pierre S, Baker SR. Squamous cell carcinoma of the maxillary sinus: analysis of 66 cases. *Head Neck Surg* 1983;5:508–13.
127. Sakai S, Hohki A, Fuchihata H, Tanaka Y. Multidisciplinary treatment of maxillary sinus carcinoma. *Cancer* 1983;52:1360–4.
128. Sakai S, Murata M, Sasaki R, Tsujimoto T, Miyaguchi M, Hohki A. Combined therapy for maxillary sinus carcinoma with special reference to cryosurgery. *Rhinology* 1983;21:179–84.
129. Flores AD, Anderson DW, Doyle PJ, Jackson SM, Morrison MD. Paranasal sinus malignancies—a retrospective analysis of treatment methods. *J Otolaryngol* 1984;13:141–6.
130. Gadeberg CC, Hjelm-Hansen M, Sogaard H, Elbrond O. Malignant tumors of the paranasal sinuses and nasal cavity. *Acta Radiol* 1984;23:181–7.
131. Klintenberg C, Olofsson J, Hellquist H, Sokjer H. Adenocarcinoma of the ethmoid sinuses. A review of 28 cases with special reference to wood dust exposure. *Cancer* 1984;54:482–8.
132. LeLiever JC, Bailey BJ, Griffiths C. Carcinoma of the nasal septum. *Arch Otolaryngol* 1984;110:748–51.
133. McNicoll W, Hopkin N, Dalley VM, Shaw HJ. Cancer of the paranasal sinuses and nasal cavities. Part II: results of treatment. *J Laryngol Otol* 1984;98:707–18.
134. Shidnia H, Hornback NB, Saghafi N, Sayoc E, Lingeman R, Hamaker R. The role of radiation therapy in treatment of malignant tumors of the paranasal sinuses. *Laryngoscope* 1984;94:102–6.
135. Hordijk GJ, Brons EN. Carcinomas of the maxillary sinus: a retrospective study. *Clin Otolaryngol* 1985;10:285–8.
136. Knegt PP, de Jong PC, van Andel JG, de Boer MF, Eykenboom W, van der Schans E. Carcinoma of the paranasal sinuses. Results of a prospective pilot study. *Cancer* 1985;56:57–62.

137. Kondo M, Ogawa K, Inuyama Y, Yamashita S, Tominaga S, Shigematsu N, et al. Prognostic factors influencing relapse of squamous cell carcinoma of the maxillary sinus. *Cancer* 1985;55:190-6.
138. Korzeniowski S, Reinfuss M, Skolyszewski J. The evaluation of radiotherapy after incomplete surgery in patients with carcinoma of the maxillary sinus. *Int J Radiat Oncol Biol Phys* 1985;11:505-9.
139. Mundy EA, Neiders ME, Sako K, Greene GW. Maxillary sinus cancer: a study of 33 cases. *J Oral Pathol* 1985;14:27-36.
140. Backhouse TW. The treatment of malignant tumours of the maxillary antrum. *Clin Radiol* 1986;37:179-82.
141. Errington RD. Advanced carcinoma of the paranasal sinuses treated with 7.5 MeV fast neutrons. *Bull Cancer* 1986;73:569-76.
142. Olmi P, Cellai E, Chiavacci A, Fallai C. Paranasal sinuses and nasal cavity cancer: different radiotherapeutic options, results and late damages. *Tumori* 1986;72:589-95.
143. Schlappack OK, Dobrowsky W, Schratte M, et al. Strahlentherapie der Nasennebenhöhlenkarzinome. *Strahlenther Onkol* 1986;162:291-9.
144. Tsujii H, Kamada T, Aromoto T, et al. Role of radiotherapy in the management of maxillary sinus carcinomas. *Cancer* 1985;57(1):2261-6.
145. Cellini N, De Santis M, Mantello G, Stella C, Trodella L, Valentini V. Radiation therapy of cancer of the paranasal sinuses: a report of 86 patients. *Rays* 1987;12:71-9.
146. Lindeman P, Eklund U, Petruson B. Survival after surgical treatment in maxillary neoplasms of epithelial origin. *J Laryngol Otol* 1987;101:564-8.
147. Shidnia H, Hartsough AB, Weisberger E, Hornback NB. Epithelial carcinoma of the nasal fossa. *Laryngoscope* 1987;97:717-23.
148. Zbären P, Richard JM, Schwaab G, Mamelle G. Malignome der Nasen und Nasennebenhöhlen. *HNO* 1987;35:256-49.
149. Hawkins RB, Wynstra JH, Pilepich MV, Fields JN. Carcinoma of the nasal cavity—results of primary and adjuvant radiotherapy. *Int J Radiat Oncol Biol Phys* 1988;15:1129-33.
150. Har-El G, Hadar T, Krespi YP, Abraham A, Sidi J. Clinical experiences with carcinoma of the maxillary sinus. *Ear Nose Throat J* 1988;67:494-7,500-2,7,8.
151. Parsons JT, Mendenhall WM, Mancuso AA, Cassisi NJ, Million RR. Malignant tumors of the nasal cavity and ethmoid and sphenoid sinuses. *Int J Radiat Oncol Biol Phys* 1988;14:11-22.
152. Debry C, Bouillon F, Methlin A, Jung C, Conraux C. Cancers du maxillaire superieur. Etude retrospective a partir de 29 cas. *Ann Otolaryngol Chir Cervicofac* 1989;106:83-90.
153. Sakata K, Akanuma A, Aoki Y, Karasawa K, Nakagawa K, Iio M. Carcinoma of the maxillary sinus: the role of radiotherapy. *Radiat Med* 1989;7:293-7.
154. Sisson GA Sr., Toriumi DM, Atiyah RA. Paranasal sinus malignancy: a comprehensive update. *Laryngoscope* 1989;99:143-50.
155. Spiro JD, Soo KC, Spiro RH. Squamous carcinoma of the nasal cavity and paranasal sinuses. *Am J Surg* 1989;158:328-32.
156. Tran L, Sidrys J, Horton D, Sadeghi A, Parker RG. Malignant salivary gland tumors of the paranasal sinuses and nasal cavity. The UCLA experience. *Am J Clin Oncol* 1989;12:387-92.
157. Zaharia M, Salem LE, Travezan R, Moscol A, Pinillos L, Farias C, et al. Postoperative radiotherapy in the management of cancer of the maxillary sinus. *Int J Radiat Oncol Biol Phys* 1989;17:967-71.
158. Anniko M, Franzen L, Lofroth PO. Long-term survival of patients with paranasal sinus carcinoma. *ORL J Otorhinolaryngol Relat Spec* 1990;52:187-93.
159. Isaacs JH Jr., Mooney S, Mendenhall WM, Parsons JT. Cancer of the maxillary sinus treated with surgery and/or radiation therapy. *Am Surg* 1990;56:327-30.
160. Karim AB, Kralendonk JH, Njo KH, Tabak JM, Elsenaar WH, van Balen AT. Ethmoid and upper nasal cavity carcinoma: treatment, results and complications. *Radiat Oncol* 1990;19:109-20.
161. Bridger GP, Mendelsohn MS, Baldwin M, Smee R. Paranasal sinus cancer. *Aust NZ J Surg* 1991;61:290-4.
162. Logue JP, Slevin NJ. Carcinoma of the nasal cavity and paranasal sinuses: an analysis of radical radiotherapy. *Clin Oncol (R Coll Radiol)* 1991;3:84-9.
163. Jackson IT, Bailey H, Marsh WR, Juhasz P. Results and prognosis following surgery for malignant tumors of the skull base. *Head Neck* 1991;13:89-96.
164. Strohmam B, Haake K. Nasenhöhlen- und Nasennebenhöhlen-Malignome an der HNO-Klinik der Charité seit 1959. *Laryngorhinootologie* 1991;70:138-41.
165. Ang KK, Jiang GL, Frankenthaler RA, Kaanders JH, Garden AS, Delclos L, et al. Carcinomas of the nasal cavity. *Radiat Oncol* 1992;24:163-8.
166. Budihna M, Smid L. Carcinoma of the paranasal sinuses: results of treatment and some prognostic factors. *Strahlenther Onkol* 1992;168:322-7.
167. Giri SPG, Reddy EK, Gemer LS, Krishnan L, Smalley SR, Evans RG. Management of advanced squamous cell carcinoma of the maxillary sinus. *Cancer* 1992;69:657-61.
168. Kraus DH, Sterman BM, Levine HL, Wood BG, Tucker HM, Lavertu P. Factors influencing survival in ethmoid sinus cancer. *Arch Otolaryngol Head Neck Surg* 1992;118:367-72.
169. MacNab TI, Flores AD, Anderson DW. Treatment of paranasal sinus malignancy: the BCCA experience. *J Otolaryngol* 1992;21:244-8.
170. Neal AJ, Hope-Stone HF. Carcinoma of the maxillary antrum treated by pre-operative radiotherapy and radical radiotherapy alone. *J Laryngol Otol* 1992;106:1063-6.
171. Dilhuydy JM, Lagarde P, Allal AS, Becouarn Y, Soubeyran P, Richaud P, et al. Ethmoidal cancers: a retrospective study of 22 cases. *Int J Radiat Oncol Biol Phys* 1993;25:113-6.
172. Nunez F, Suarez C, Alvarez I, Losa JL, Barthe P, Fresno M. Sino-nasal adenocarcinoma: epidemiological and clinicopathological study of 34 cases. *J Otolaryngol* 1993;22:86-90.
173. Sakata K, Aoki Y, Karasawa K, et al. Analysis of results of combined therapy for maxillary carcinoma. *Cancer* 1993;71:2715-22.
174. Stern SJ, Geopfert H, Clayman G, Byers R, Ang KK, el-Naggar AK, et al. Squamous cell carcinoma of the maxillary sinus. *Arch Otolaryngol Head Neck Surg* 1993;119:964-9.
175. Gabriele P, Orecchia R, Valente G, et al. Risultati della radioterapia nel trattamento dei tumori maligni della fossa nasale e del vestibolo. *Radiol Med (Torino)* 1994;87:853-7.
176. Janecka IP, Sen C, Sekhar L, Curtin H. Treatment of paranasal sinus cancer with cranial base surgery: results. *Laryngoscope* 1994;104:553-5.
177. Krengli M, Gabriele P, Turri L, Ruo Redda MG, Pisani P, Negri G. La radioterapia esclusiva dei tumori dei seni paranasali. Analisi retrospettiva di 73 casi. *Radiol Med (Torino)* 1994;88:291-4.

178. McCaffrey TV, Olsen KD, Yohanan JM, Lewis JE, Ebersold MJ, Piepgras DG. Factors affecting survival of patients with tumors of the anterior skull base. *Laryngoscope* 1994;104:940–5.
179. Shibuya H, Hoshina M, Shagdarsuren M, Hoshi A, Matsumoto S, Suzuki S, et al. Squamous cell carcinoma of the maxillary sinus and the oral part of the upper jaw. Comparison of treatment results. *Acta Oncol* 1994;33:43–7.
180. Alvarez I, Suarez C, Rodrigo JP, Nunez F, Caminero MJ. Prognostic factors in paranasal sinus cancer. *Am J Otolaryngol* 1995;16:109–14.
181. Haraguchi H, Ebihara S, Saikawa M, Mashima K, Tatsumasa H, Hirano K. Malignant tumors of the nasal cavity: review of a 60-case series. *Jpn J Clin Oncol* 1995;25:188–94.
182. Spiro JD, Soo KC, Spiro RH. Nonsquamous cell malignant neoplasms of the nasal cavities and paranasal sinuses. *Head Neck* 1995;17:114–8.
183. Carinci F, Farina A, Padula E, Calearo C. Primary malignancies of the nasal fossa and paranasal sinuses: comparison between UICC classification and a new staging system. *J Craniofac Surg* 1997;8:405–12.
184. Harbo G, Grau C, Bundgaard T, Overgaard M, Elbrond O, Sogaard H, et al. Cancer of the nasal cavity and paranasal sinuses. A clinico-pathological study of 277 patients. *Acta Oncol* 1997;36:45–50.
185. Jakobsen MH, Larsen SK, Kirkegaard J, Hansen HS. Cancer of the nasal cavity and paranasal sinuses. Prognosis and outcome of treatment. *Acta Oncol* 1997;36:27–31.
186. Paulino AC, Marks JE, Bricker P, Melian E, Reddy SP, Emami B. Results of treatment of patients with maxillary sinus carcinoma. *Cancer* 1998;83:457–65.
187. Svane-Knudsen V, Jorgensen KE, Hansen O, Lindgren A, Marker P. Cancer of the nasal cavity and paranasal sinuses: a series of 115 patients. *Rhinology* 1998;36:12–4.
188. Waldron JN, O'Sullivan B, Warde P, Gullane P, Lui FF, Payne D, et al. Ethmoid sinus cancer: twenty-nine cases managed with primary radiation therapy. *Int J Radiat Oncol Biol Phys* 1998;41:361–9.
189. Lund VJ, Howard DJ, Wei WI, Cheesman AD. Craniofacial resection for tumors of the nasal cavity and paranasal sinuses—a 17-year experience. *Head Neck* 1998;20(2):97–105.
190. Cantu G, Solero CL, Mariani L, Salvatori P, Mattavelli F, Pizzi N, et al. Anterior craniofacial resection for malignant ethmoid tumors—a series of 91 patients. *Head Neck* 1999;21:185–91.
191. Carrau RL, Segas J, Nuss DW, Snyderman CH, Janecka IP, Myers EN, et al. Squamous cell carcinoma of the sinonasal tract invading the orbit. *Laryngoscope* 1999;109:230–5.
192. Franchi A, Gallo O, Santucci M. Clinical relevance of the histological classification of sinonasal intestinal-type adenocarcinomas. *Hum Pathol* 1999;30:1140–5.
193. Lee MM, Vokes EE, Rosen A, Witt ME, Weichselbaum RR, Haraf DJ. Multimodality therapy in advanced paranasal sinus carcinoma: superior long-term results. *Cancer J Sci Am* 1999;5:219–23.
194. Kim GE, Chung EJ, Lim JJ, Keum KC, Lee SW, Cho JH, et al. Clinical significance of neck node metastasis in squamous cell carcinoma of the maxillary antrum. *Am J Otolaryngol* 1999;20:383–90.
195. Tiwari R, Hardillo JA, Tobi H, Mehta D, Karim AB, Snow G. Carcinoma of the ethmoid: results of treatment with conventional surgery and post-operative radiotherapy. *Eur J Surg Oncol* 1999;25:401–5.
196. Allal AS, Dilhuydy JM, Lagarde P, Stoll D, Benhaddou M, Richaud P, et al. Place de la radiothérapie dans le cancer de l'ethmoïde. Etude rétrospective d'une série de vingt-quatre cas. *Ann Radiol (Paris)* 1991;34:221–5.
197. Van Tuyl R, Gussack GS. Prognostic factors in craniofacial surgery. *Laryngoscope* 1991;101:240–4.
198. Bridger GP, Baldwin M. Anterior craniofacial resection for ethmoid and nasal cancer with free flap reconstruction. *Arch Otolaryngol Head Neck Surg* 1989;115:308–12.
199. Panje WR, Dohrmann GJ III, Pitcock JK, Scher N, Weichselbaum RR, Sutton HG Jr., et al. The transfacial approach for combined anterior craniofacial tumor ablation. *Arch Otolaryngol Head Neck Surg* 1989;115:301–7.
200. Frierson HF, Mills SE, Fechner RE, Taxy JB, Levine PA. Sinonasal undifferentiated carcinoma. An aggressive neoplasm derived from Schneiderian epithelium and distinct from olfactory neuroblastoma. *Am J Surg Pathol* 1986;10:771–9.
201. Helliwell TR, Yeoh LH, Stell PM. Anaplastic carcinoma of the nose and paranasal sinuses. *Cancer* 1986;58:2038–45.
202. Welch HG, Schwartz LM, Woloshin S. Are increasing 5-year survival rates evidence of success against cancer? *JAMA* 2000;283:2975–8.
203. Carinci F, Curioni C, Padula E, Calearo C. Cancer of the nasal cavity and paranasal sinuses: a new staging system. *Int J Oral Maxillofac Surg* 1996;25:34–9.
204. Dileo MD, Miller RH, Rice JC, Butcher RB. Nasal septum squamous cell carcinoma: a chart review and meta-analysis. *Laryngoscope* 1996;106:1218–22.
205. Rosen A, Vokes EE, Scher N, Haraf D, Weichselbaum RR, Panje WR. Locoregionally advanced paranasal sinus carcinoma. Favorable survival with multimodality therapy. *Arch Otolaryngol Head Neck Surg* 1993;119:743–6.
206. Kraus DH, Roberts JK, Medendorp SV, Levine HL, Wood BG, Tucker HM, et al. Nonsquamous cell malignancies of the paranasal sinuses. *Ann Otol Rhinol Laryngol* 1990;99:5–11.
207. Dulguerov P, Allal AS, Calcaterra TC. Esthesioneuroblastoma—a meta-analysis and review. *Lancet* (in press).
208. Graamans K, Slootweg PJ. Orbital exenteration in surgery of malignant neoplasms of the paranasal sinuses. The value of preoperative computed tomography. *Arch Otolaryngol Head Neck Surg* 1989;115:977–80.
209. Larsson DL, Christ JE, Jesse RH. Preservation of orbital contents in cancer of the maxillary sinus. *Arch Otolaryngol Head Neck Surg* 1982;108:370–2.
210. Perry C, Levine PA, Williamson BR, Cantrell RW. Preservation of the eye in paranasal sinus cancer surgery. *Arch Otolaryngol Head Neck Surg* 1988;114:632–4.
211. McCary WS, Levine PA. Management of the eye in the treatment of sinonasal cancers. *Otolaryngol Clin North Am* 1995;28:1231–8.
212. McCary WS, Levine PA, Cantrell RW. Preservation of the eye in the treatment of sinonasal malignant neoplasms with orbital involvement. A confirmation of the original treatise. *Arch Otolaryngol Head Neck Surg* 1996;122:657–9.
213. Paulino AC, Fisher SG, Marks JE. Is prophylactic neck irradiation indicated in patients with squamous cell carcinoma of the maxillary sinus? *Int J Radiat Oncol Biol Phys* 1997;39:283–9.
214. del Regato JA. Roentgentherapy in epitheliomas of the maxillary sinus. *Surg Gynecol Obstet* 1937;65:657–65.